

Thrombozytenreiches Plasma und Manuelle Medizin

Behandlungsmöglichkeiten an der Wirbelsäule

SAMM Kongress 2021

Dr. med. Moritz Dau, Rheinfelden

Interventionelle Schmerztherapie SSIPM

Ultraschall am Bewegungsapparat SGUM

Manuelle Medizin SAMM

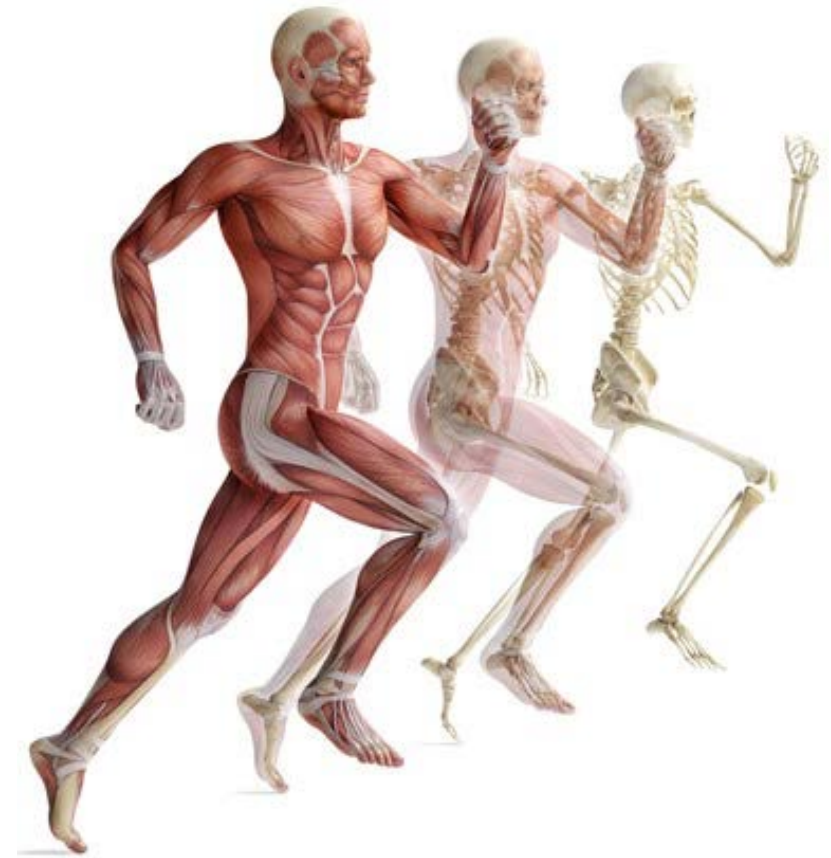Sportmedizin SEMS

www.ortholink.ch

Orthopädie

am Rhy

**Gezielte
Behandlungsmöglichkeiten
mit
thrombozytenreichem Plasma PRP
an der Wirbelsäule
ergänzend zur
manuellen Therapie**



Dr. med. Moritz Dau, Rheinfelden
Interventionelle Schmerztherapie SSIPM
Ultraschall am Bewegungsapparat SGUM
Manuelle Medizin SAMM
Sportmedizin SEMS
www.ortholink.ch

Orthopädie
am Rhy

Thrombozytenreiches Plasma und manuelle Medizin

- Eine Symbiose?

Warum passen PRP und die manuelle Medizin gut zusammen:

Wir wollen mit beiden Methoden

- ✓ Regeneration ermöglichen und anregen
- ✓ Physiologische Verhältnisse wiederherstellen
- ✓ Gewebekompetenz stärken und Gelenke stabilisieren
- ✓ Steroide und NSAR einsparen

Thrombozytenreiches Plasma und manuelle Medizin

- Eine Symbiose?

Für eine erfolgreiche PRP Therapie an der Wirbelsäule brauchen wir

- ✓ Kompetenz in der (diagnostischen) manuellen Medizin
- ✓ Verständnis der funktionellen Anatomie des Bewegungsapparates
- ✓ um die betroffene Struktur exakt zu identifizieren
- ✓ die korrekte Diagnose zu stellen
- ✓ um PRP an den richtigen Ort zu bringen (ggf. US oder BV-gesteuert)

Inhalt:

Was ist PRP?

Biochemie und Wirkung

Indikationen

Studien/Evidenz

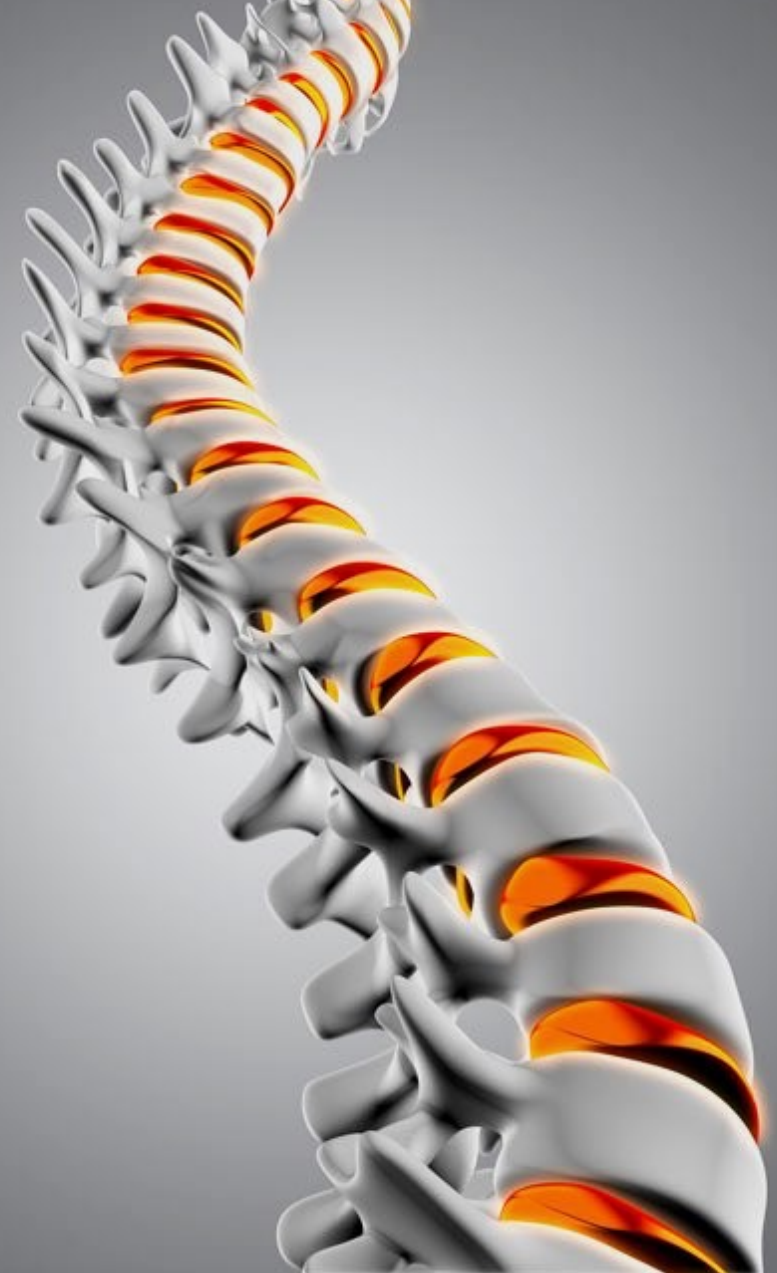BWA und WS

Anwendungen und eigenes Vorgehen

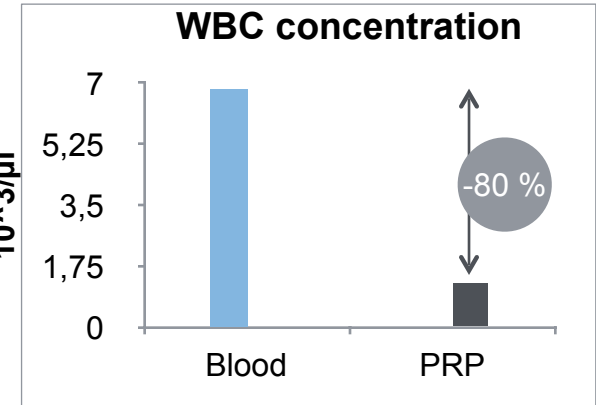
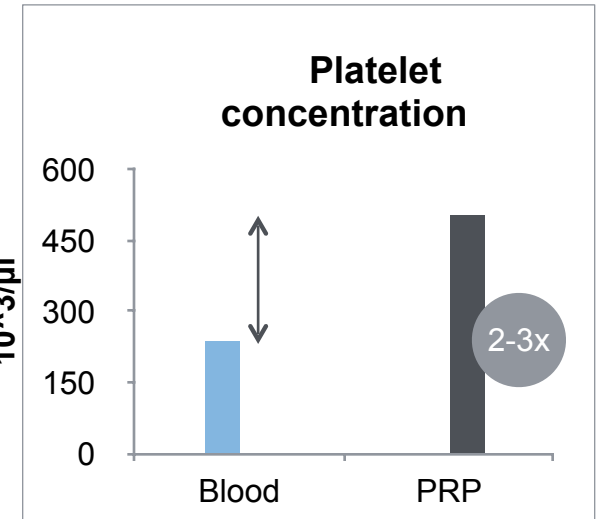
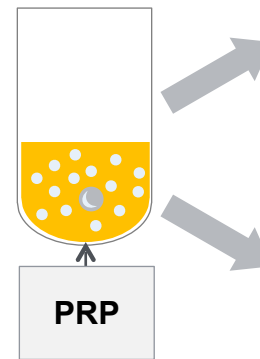
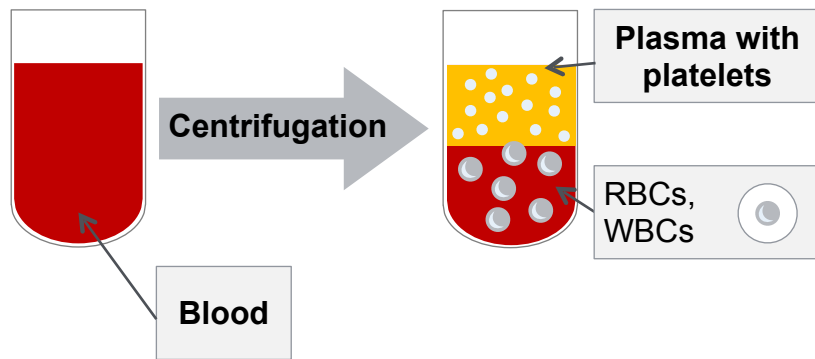
- ★ Fallbeispiel cervicale Facetten
- ★ Fallbeispiel Costotransversalgelenke

Nachteile

Take home



Plasma-Based PRP



PRP Production – The Principle

Density Distribution of Blood Components

A – Platelets

B – Monocytes

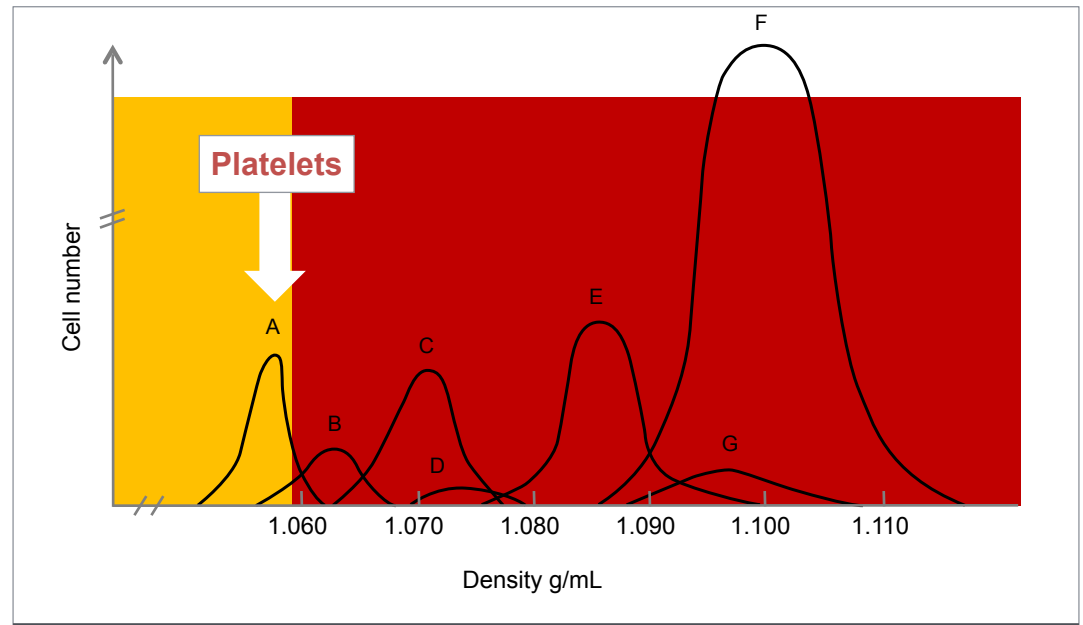
C – Lymphocytes

D – Basophils

E – Neutrophils

F – Erythrocytes

G – Eosinophils



Efficacy of PRP – Components

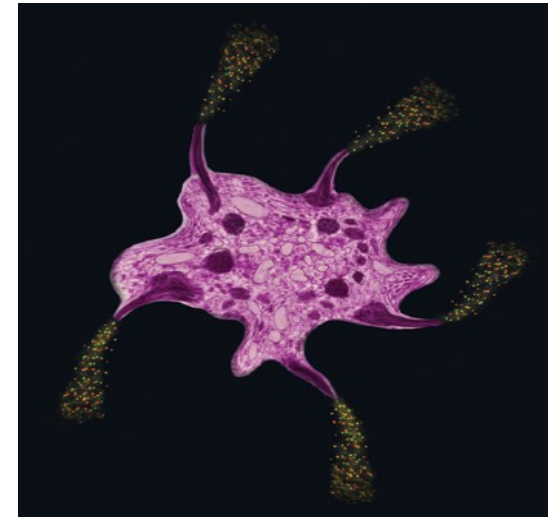
Thrombocytes/
platelets

α Granules

- Growth factors

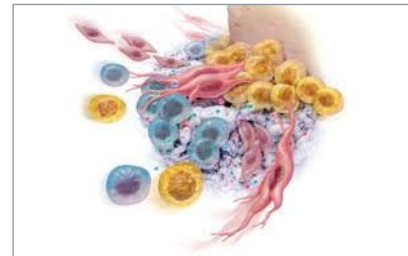
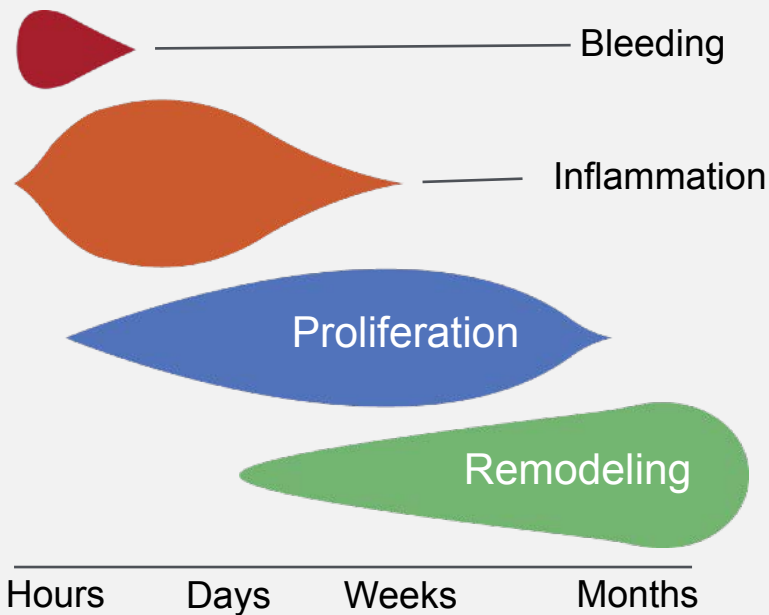
D Granules (Dense, Electron-Dense)

- Serotonin, ADP/ATP, catecholamines

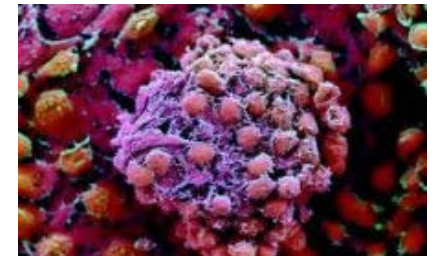

Growth Factors – Mode of Action

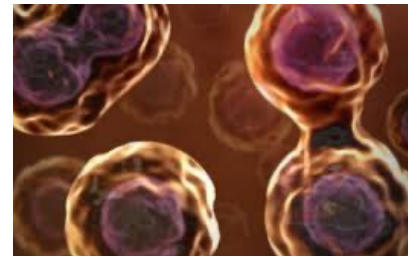
Tissue Repair Phase and Timescale



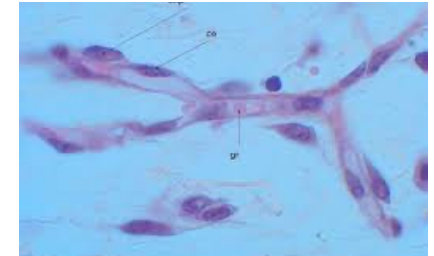
Chemotaxis



Cell Differentiation



Cell Proliferation
(e.g. Osteoblasts, Tenocytes, Myocytes)



Angiogenesis

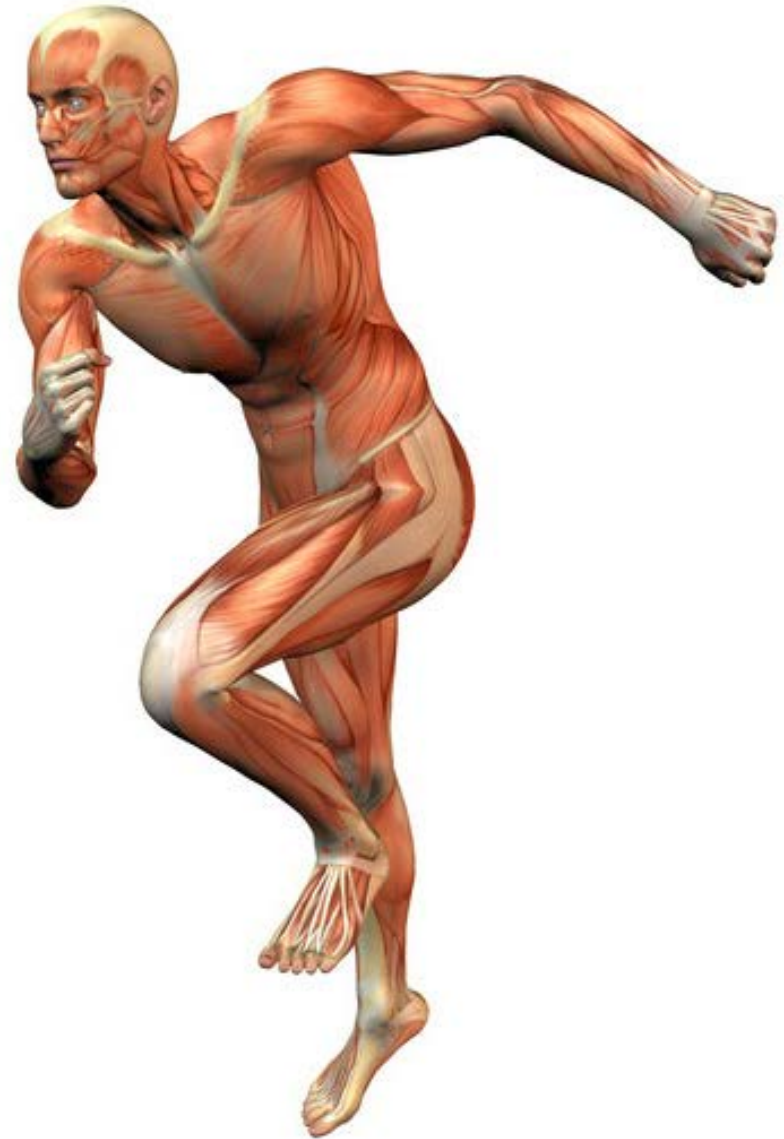Mazzocca et al., AJSM 2012

Action:

Faster regeneration time

Pain reduction

Improved function

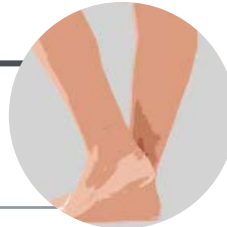


Indications of PRP - MSK

Acute

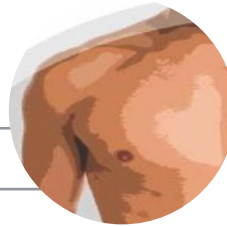Tendon Injuries

- Achilles tendon
- Rotator cuff



Ligamentous Injuries

- ACL
- Medial collateral ligament
- Ankle ligaments



Torn muscle fibers

Intra- / Post-Op

- RC
 - Pain reduction
 - Meniscus
 - ACL
-

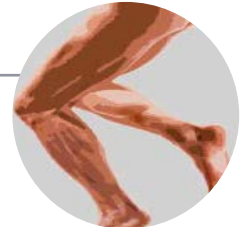Chronic

Osteoarthritis

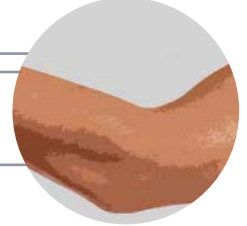
- I, II, III

Tendinopathies

- Achilles tendon
- Tennis elbow
- Patellar tendon
- Plantar tendon



Ligamentosis



Rheuma / Inflammatory

Rheuma

non Rheumatic

- Retractable Capsulitis
-

Scientific Proof? Evidence?

Save

Email

Send to

Sorted by: Best match

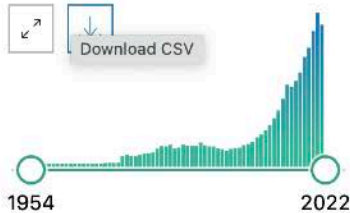
Display options ⚙

MY NCBI FILTERS

13,717 results

Page 1 of 1,372

RESULTS BY YEAR



TEXT AVAILABILITY

- Abstract
- Free full text
- Full text

ARTICLE ATTRIBUTE

- Associated data

Platelet-Rich Plasma.

1 Wu PI, Diaz R, Borg-Stein J.

Cite Phys Med Rehabil Clin N Am. 2016 Nov;27(4):825-853. doi: 10.1016/j.pmr.2016.06.002.
 PMID: 27788903 Review.

Share **Platelet-rich plasma** (PRP) is a growing and robust therapeutic option in musculoskeletal medicine. PRP is a preparation of autologous **plasma** enriched with a **platelet** concentration above that normally contained in whole blood. ...

Platelet-rich plasma: myth or reality?

2 Martínez-Martínez A, Ruiz-Santiago F, García-Espinosa J.

Cite Radiologia (Engl Ed). 2018 Nov-Dec;60(6):465-475. doi: 10.1016/j.rx.2018.08.006. Epub 2018 Sep 28.

Share PMID: 30274850 **Free article.** Review. English, Spanish.

Platelet-rich plasma (PRP) is a preparation for therapeutic purposes that is increasingly accepted for various musculoskeletal disorders, due to its theoretical potential to repair tissues with poor healing capacity. ...

Save

Email

Send to

Sorted by: Best match

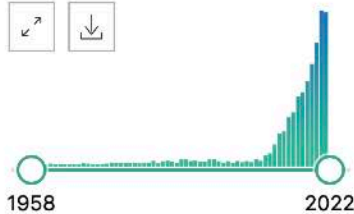
Display options ⚙

MY NCBI FILTERS

2,734 results

Page 1 of 274

RESULTS BY YEAR



TEXT AVAILABILITY

- Abstract
- Free full text
- Full text

ARTICLE ATTRIBUTE

- Associated data

Platelet-Rich Plasma.

1 Wu PI, Diaz R, Borg-Stein J.

Cite Phys Med Rehabil Clin N Am. 2016 Nov;27(4):825-853. doi: 10.1016/j.pmr.2016.06.002.
PMID: 27788903 Review.

Share **Platelet-rich plasma (PRP)** is a growing and robust therapeutic option in musculoskeletal medicine. PRP is a preparation of autologous **plasma** enriched with a **platelet** concentration above that normally contained in whole blood. ...

Intra-articular platelet-rich plasma injection for knee osteoarthritis: a summary of meta-analyses.

2 Chen P, Huang L, Ma Y, Zhang D, Zhang X, Zhou J, Ruan A, Wang Q.

Cite J Orthop Surg Res. 2019 Nov 27;14(1):385. doi: 10.1186/s13018-019-1363-y.
PMID: 31775816 **Free PMC article.** Review.

Share OBJECTIVE: The purpose of this study was (1) to perform a summary of meta-analyses comparing **platelet-rich plasma (PRP) injection** with hyaluronic acid (HA) and placebo **injection** for KOA patients, (2) to determine which meta-analysis provides the ...

PRP in Knee OA — Evidence

Basic Science

Buul et al, AJSM, 2011
Andia et al, Op. Tech. Ortho, 2012
Smyth et al, Arthroscopy, 2013
Anitua et al, J Biomed Mat.Res, 2014
Braun et al, AJSM, 2014
Sundman et al, AJSM, 2014

Reviews

Filardo et al, KSSTA 2013
Koshbin et al, JARS 2013
Chang et al, ACRM 2013
Pourcho et al, Osteoarthritis 2014
<i>Kanchanatawan et al, KSSTA 2015</i>
Meheux et al, Arthroscopy 2015
Dai et al, Arthroscopy 2016
<i>Shen et al, JOSR 2017</i>

Level I Randomized Controlled Trials

<i>Cerza et al, AJSM, 2012</i>	ACP vs. HA
Sanchez et al, Arthroscopy, 2012	PRGF vs. HA
Paterson et al, BMC Musculoskelet Disord, 2013	PRP vs. HA
Patel et al, AJSM, 2013	PRP vs. Placebo
Vaquerizo et al, Jars, 2013	PRGF vs. HA
Filardo et al, AJSM, 2015	PRP vs. HA
Görmeli et al, KSSTA, 2015	PRP vs. HA vs. Placebo
Raeissadat et al, Clin Med Insights, 2015	PRP vs. HA
Cole et al, AJSM, 2016	ACP vs. HA
Duymus et al, KSSTA, 2016	PRP vs. HA vs. Ozone
<i>Smith et al, AJSM, 2016</i>	ACP vs. Placebo
Huang et al, Der Orthopäde 2019	ACP vs. HA, CS

Arthroscopy: The Journal of Arthroscopic and Related Surgery, Vol 33, No 3 (March), 2017: pp 671-672

OA Knee – PRP

ACP vs. Placebo (Smith, AJSM, 2016)

RCT, double-blind, regulated by the FDA, level I

30 patients

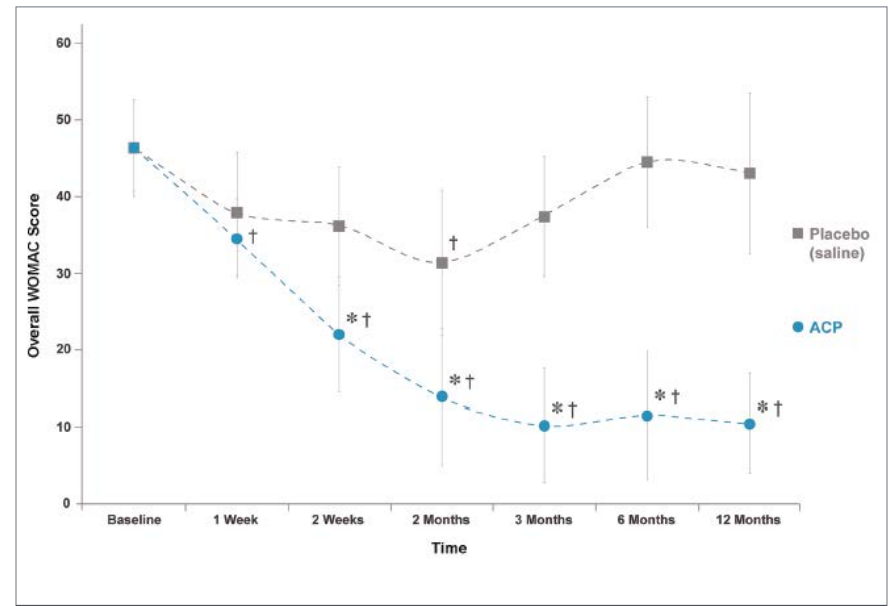
3 injections, weekly interval

OA grade II-III; WOMAC

From week 2 onwards, ACP was **significantly superior to saline placebo** up to 12 months!

ACP group improved their WOMAC scores by 78% from baseline vs. 7% for the placebo group

No adverse events



OA Knee – ACP

ACP vs. HA (Cerza, AJSM, 2012)

RCT, level I

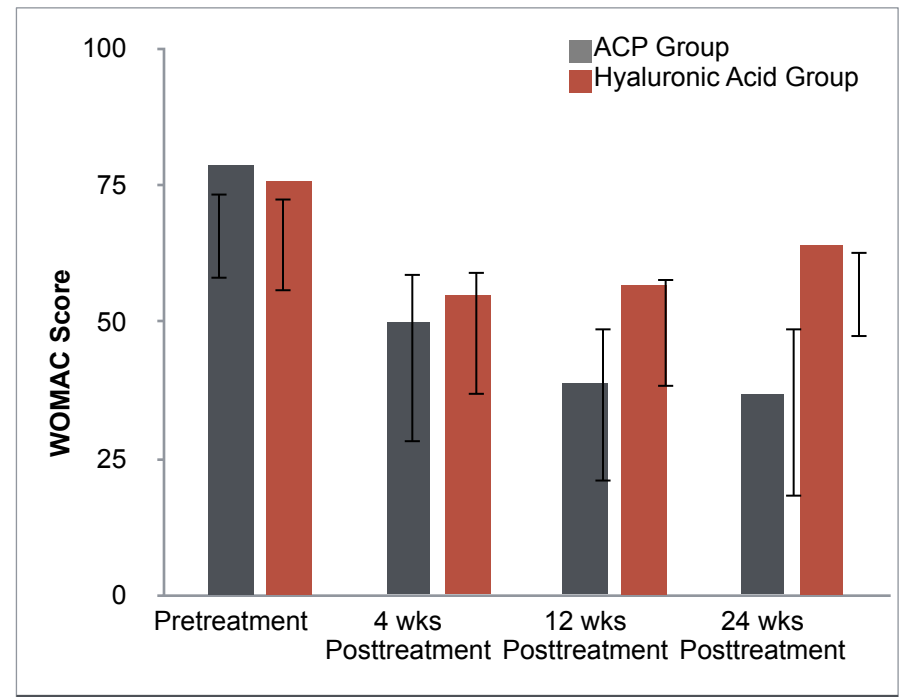
120 patients

4 injections, weekly interval

OA grade I-III, WOMAC

ACP showed a **significantly better clinical outcome** than did treatment with HA

Effective up to 6 months (up to 12 months, not published)



Review – Kanchanatawan (KSSTA, 2015, level I)

Conclusion:

This study suggests that **PRP injection is more efficacious than HA injection and placebo** in reducing symptoms, improving function and improving quality of life in patients with **mild-to-moderate OA** of the knee who have not responded to conventional treatment and therefore **can be considered as a treatment of choice**.

Review – Shen (JOSR, 2017, level I)

Conclusion:

Intra-articular **PRP injections probably are more efficacious** in the treatment of knee OA in terms of pain relief and self-reported function improvement at 3, 6 and 12 months follow-up, **compared with other injections, including saline placebo, HA, ozone, and corticosteroids**.

Gute Evidenz und Level 1 Studien:

- Behandlungen von Arthrosen
 - ➔ Gonarthrose
 - Tendinosen (Tennisellenbogen, Jumpers knee, Achillodynien)
 - Ligamentosen
- ✓ Gelenke
 - ✓ Sehnen
 - ✓ Ligamente
 - ✓ Meniscus
 - ✓ Muskeln

[1] P. A. Smith, "Intra-articular Autologous Conditioned Plasma Injections Provide Safe and Efficacious Treatment for Knee Osteoarthritis," *Am. J. Sports Med.*, vol. 44, no. 4, pp. 884–891, 2016.

[2] Y. Huang, X. Liu, X. Xu, and J. Liu, "Intra-articular injections of platelet-rich plasma, hyaluronic acid or corticosteroids for knee osteoarthritis: A prospective randomized controlled study," *Orthopade*, vol. 48, no. 3, pp. 239–247, 2019.

[3] T. E. Foster, B. L. Puskas, B. R. Mandelbaum, M. B. Gerhardt, and S. A. Rodeo, "Platelet-rich plasma: From basic science to clinical applications," *American Journal of Sports Medicine*. 2009.

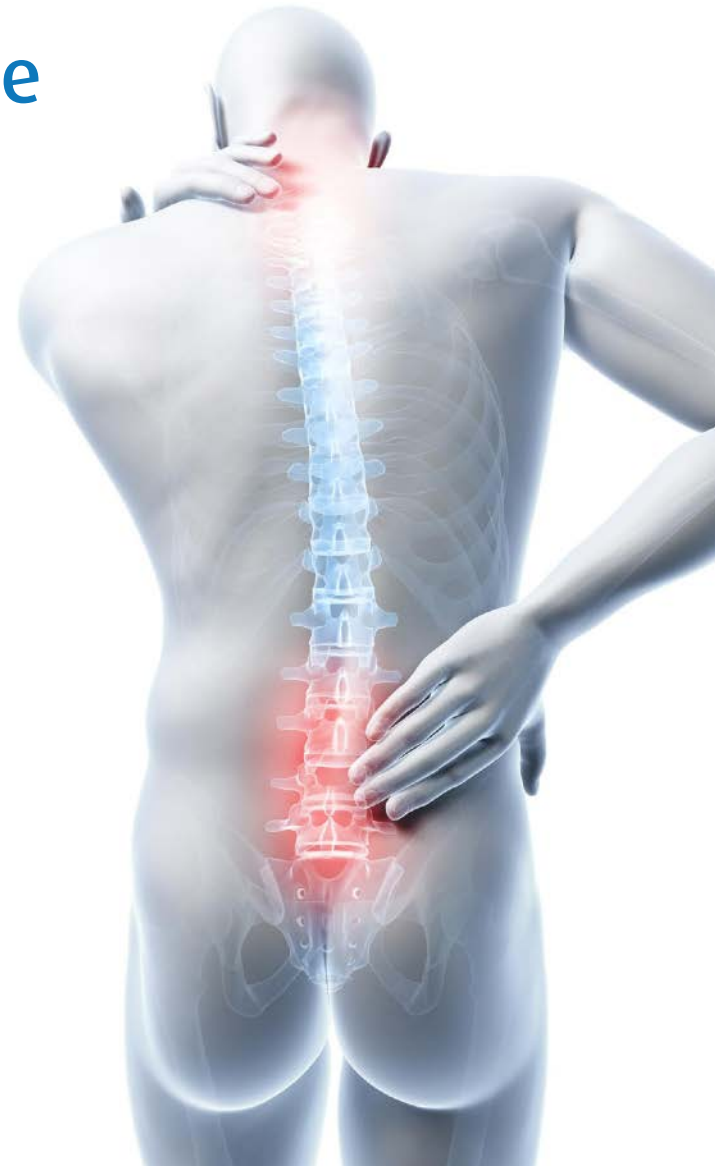[4] E. Kon et al., "Platelet-rich plasma : intra-articular knee injections produced favorable results on degenerative cartilage lesions," pp. 472–479, 2010.

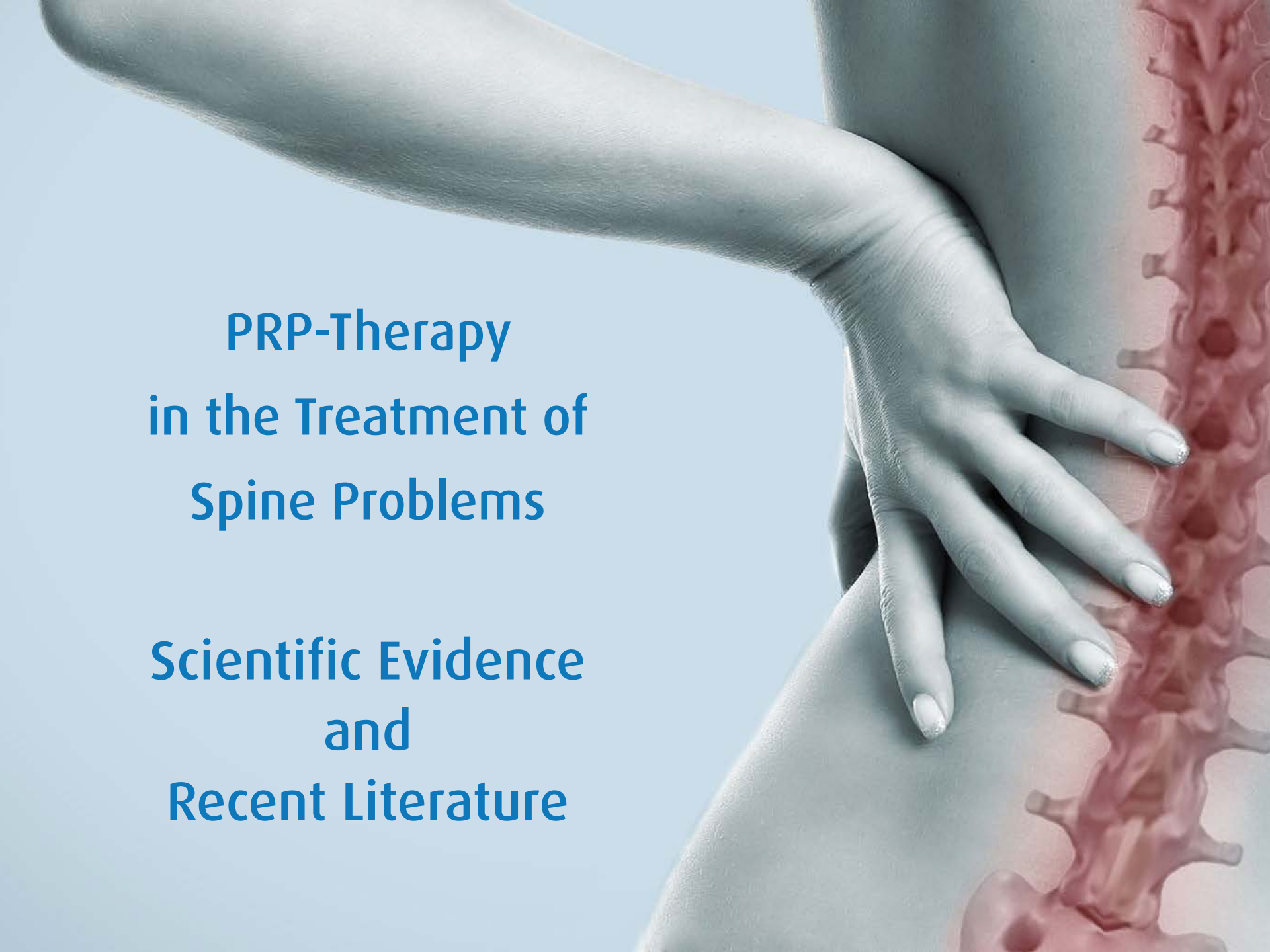
[5] A. Mishra and T. Pavelko, "Treatment of chronic elbow tendinosis with buffered platelet-rich plasma," *Am. J. Sports Med.*, 2006.

[6] M. De Mos et al., "Can platelet-rich plasma enhance tendon repair? A cell culture study," *Am. J. Sports Med.*, 2008.

PRP - Therapie an der Wirbelsäule

- ▶ Wenig Evidenz
 - ▶ aber das gleiche Gewebe...
 - ▶ Discus?
 - ▶ Nervenwurzeln?
- ✓ Gelenke
 - ✓ Sehnen
 - ✓ Ligamente
 - ✓ Meniskus
 - ✓ Muskeln

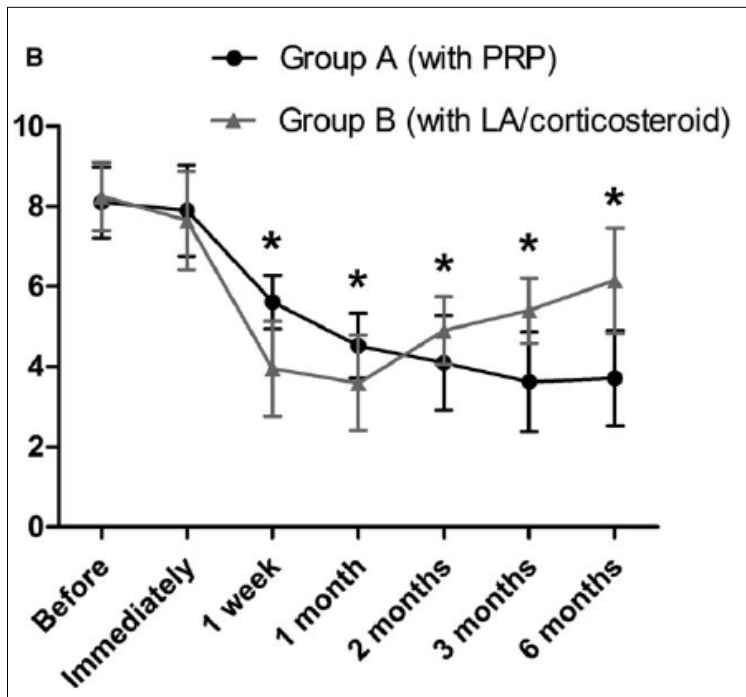


A photograph of a person's back with a hand resting on the lower back. A semi-transparent red anatomical illustration of the spine is overlaid on the right side of the image. The background is a light blue gradient.

PRP-Therapy in the Treatment of Spine Problems

Scientific Evidence and Recent Literature

Facet Joint Syndrome



Visual analog scale of low back pain during flexion

- Prospective, randomized, controlled
- 46 patients (non-responder to conservative treatment)
- Single injection: PRP vs LA/Steroid

Results

Pain decreased significantly in both groups

At 3 months pain relief was significantly better in PRP group

Functional scores improved more in LA/steroid in short-term – the opposite occurred in the long-term period

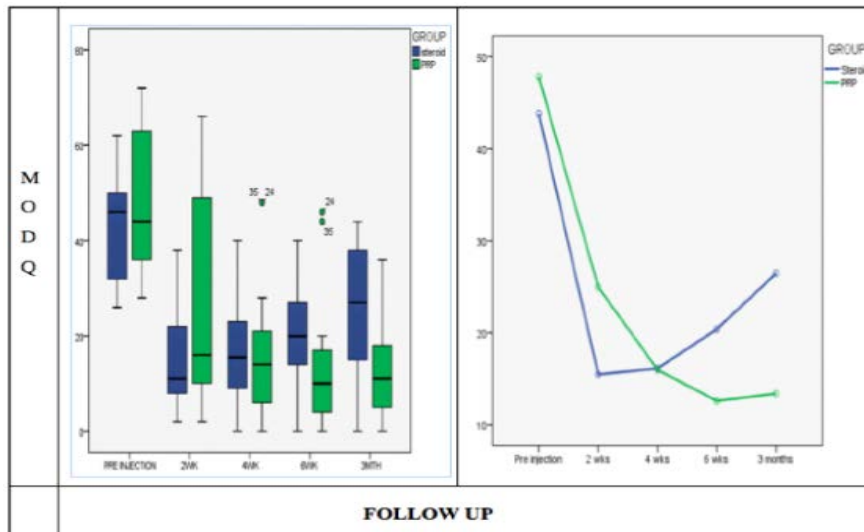
Patient satisfaction in the PRP group increased over time to 80.95% after 6 months. (versus 50% in the LA/steroid group)

Wu, Pain Practice, 2017



Chronic low back pain – sacroiliac joint

Singla, Pain Practice, 2017



Results

Intensity of pain significantly lower in PRP group at 6 weeks and 3 months

Efficacy of injection was only 25% in the steroid group at 3 months vs. 90% in PRP group

Functionality scores improved in both groups at short-term follow-up

Long-term improvement was only found in PRP group

- Prospective, randomized, open blinded
- 40 patients
- Single Ultrasound-guided injection
- LP-PRP vs. Steroid (3.5ml)

23 June 15, 2019

Artifex

My Indications for PRP

Lumbar facet joints

Pelvic ligaments (Prolotherapy)

Sacroiliac-Joint

Cervical facet joints

Thoracic facet joints

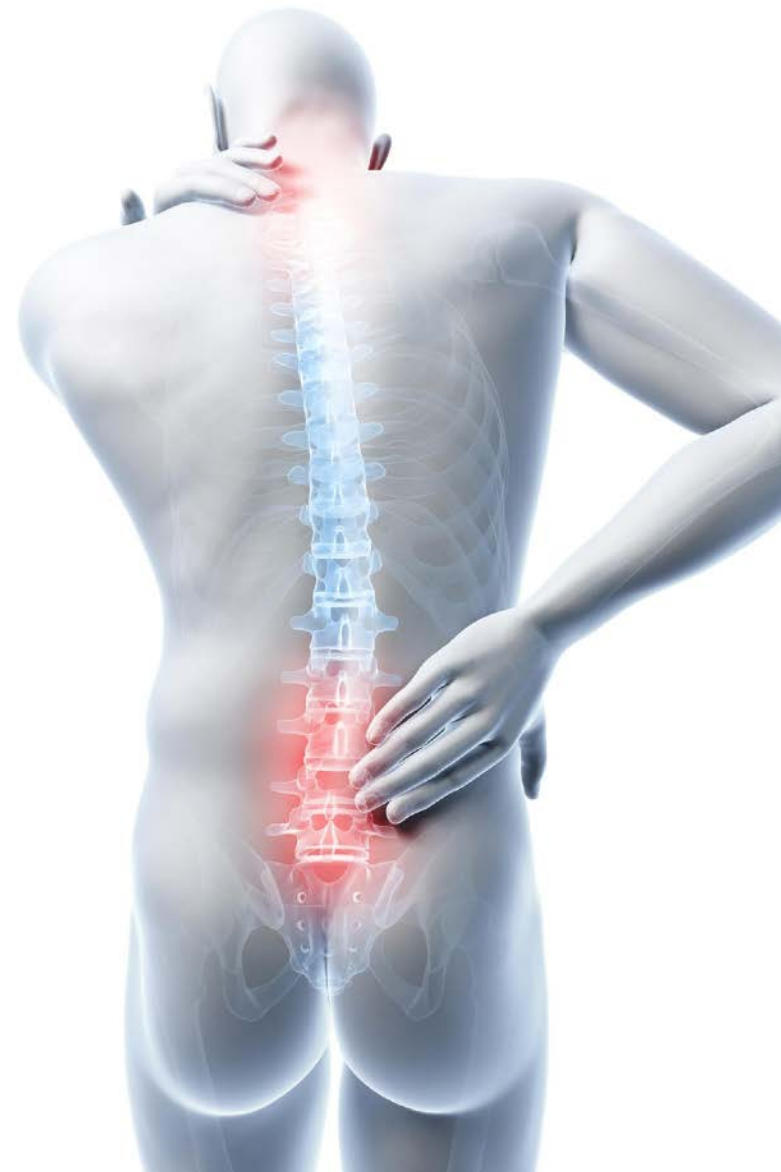Rip joints


Coccygodynia

Lumbar nerve roots

Cervical nerve roots

Discogenic pain





**PRP - Therapy
in the Treatment of
Spine Problems**

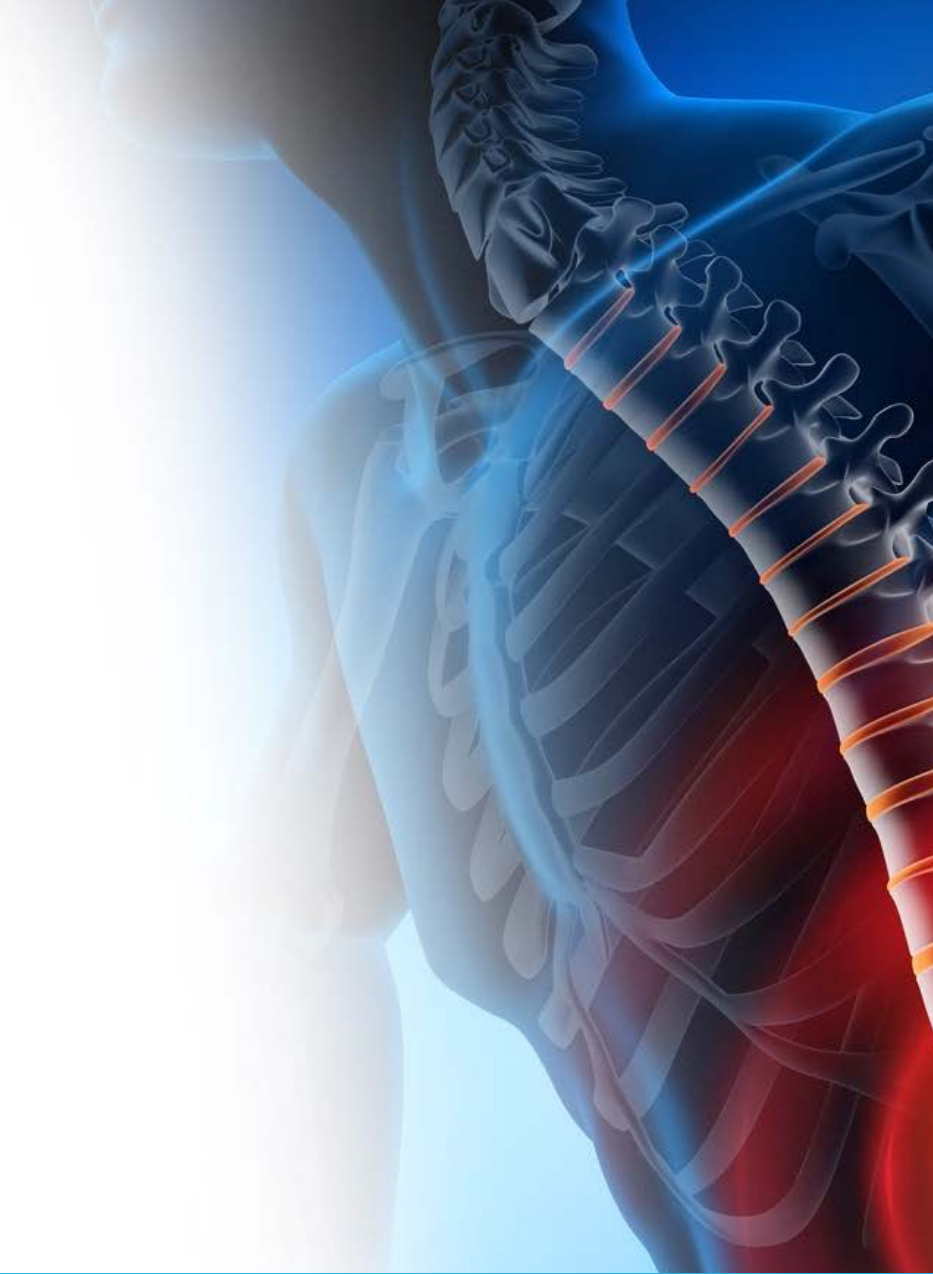
**Case Report 1
Cervical Spine**

Fall 1

54j Biologin bei Novartis

ZW bei Sz. Nacken und CTÜ re

PT und NSAR



Fall 1

54j Biologin bei Novartis

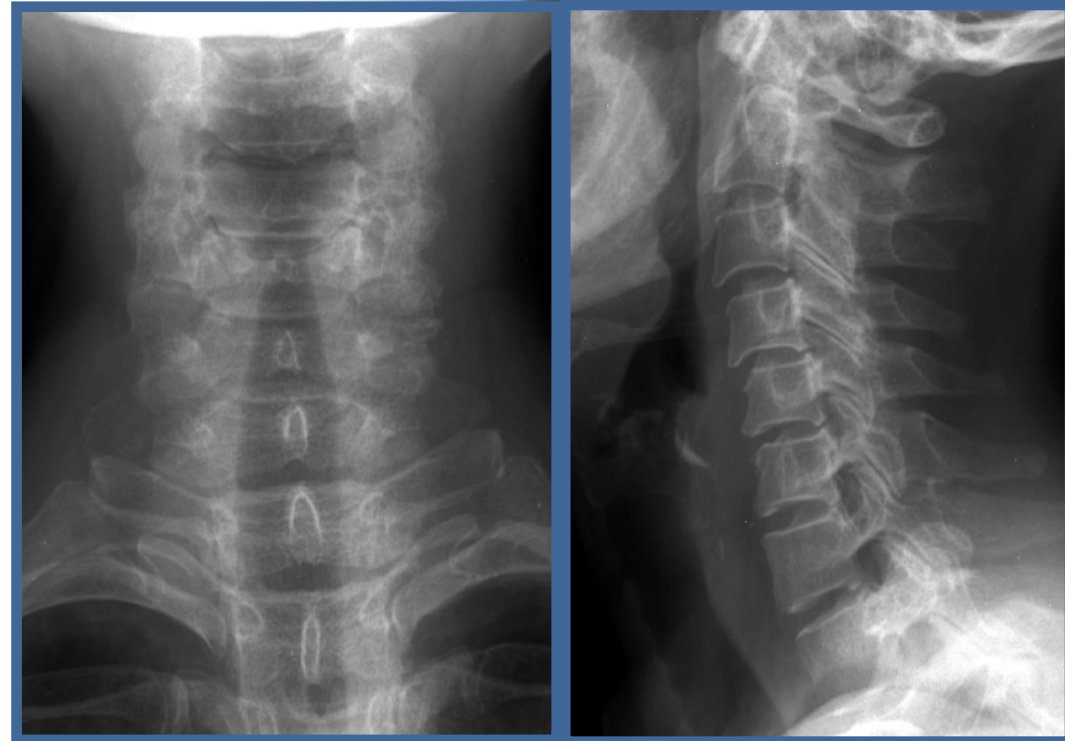
ZW bei Sz. Nacken und CTÜ re

PT und NSAR

Röntgen

Sz bei Bewegung und in Ruhe

US: Ergüsse C4/5 und C5/6



Fall 1

54j Biologin bei Novartis

ZW bei Sz. Nacken und CTÜ re

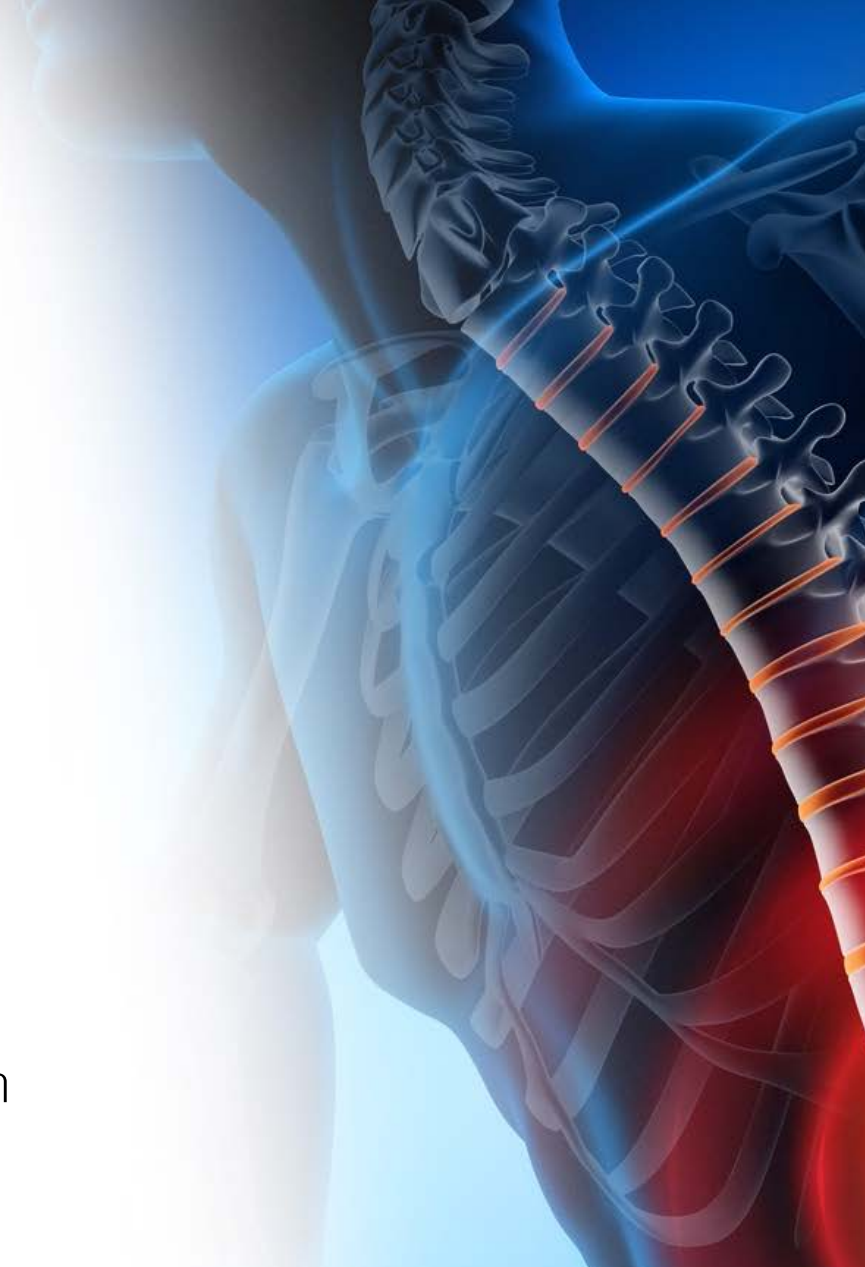
Infiltration Dexamethason/Ropivacain

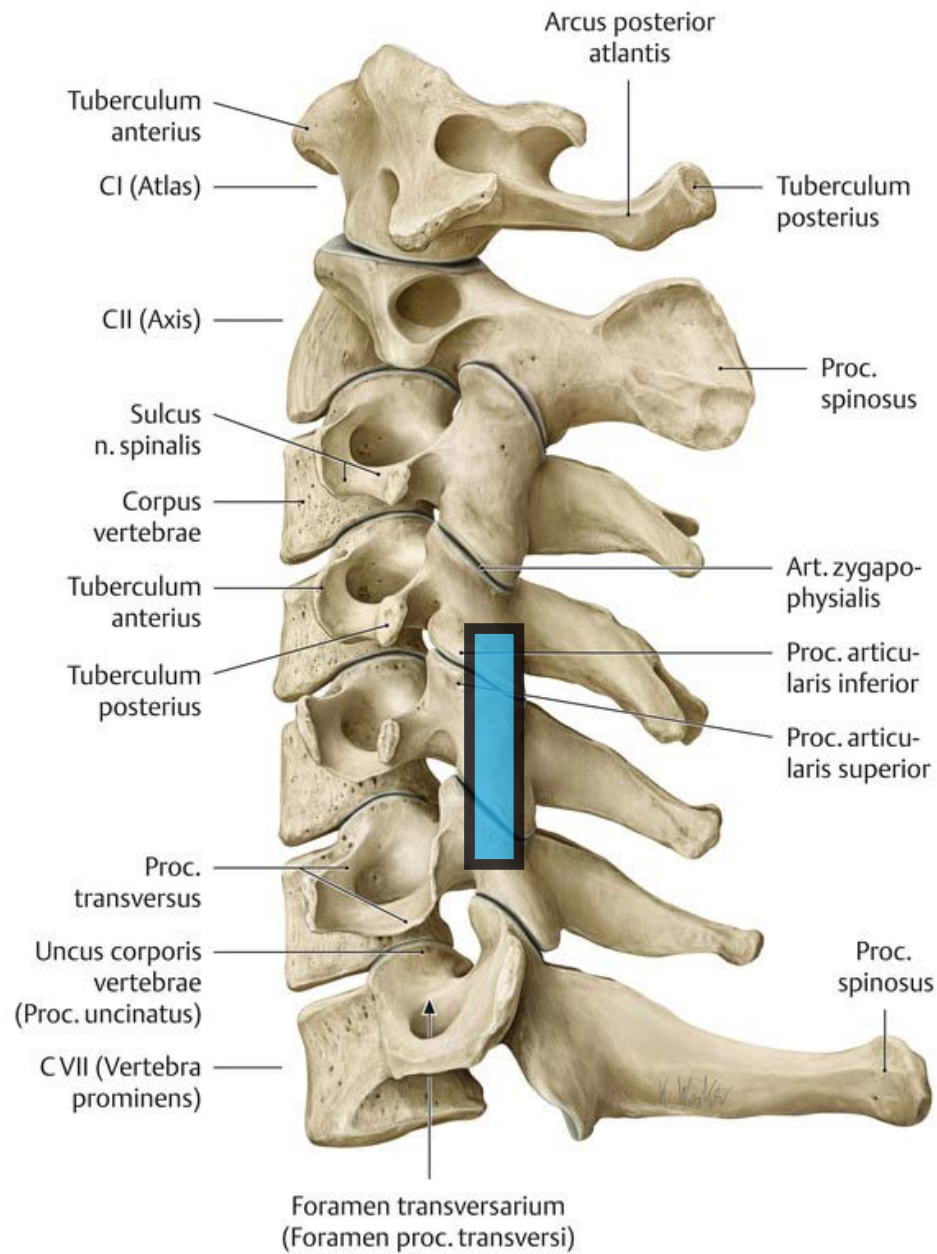
→ Besser für etwa 3 Wo (60%), NSAR >

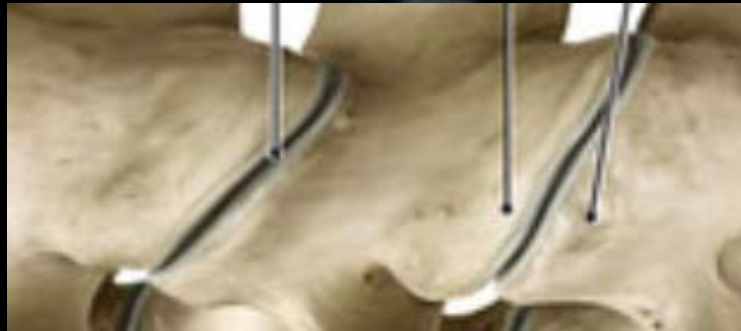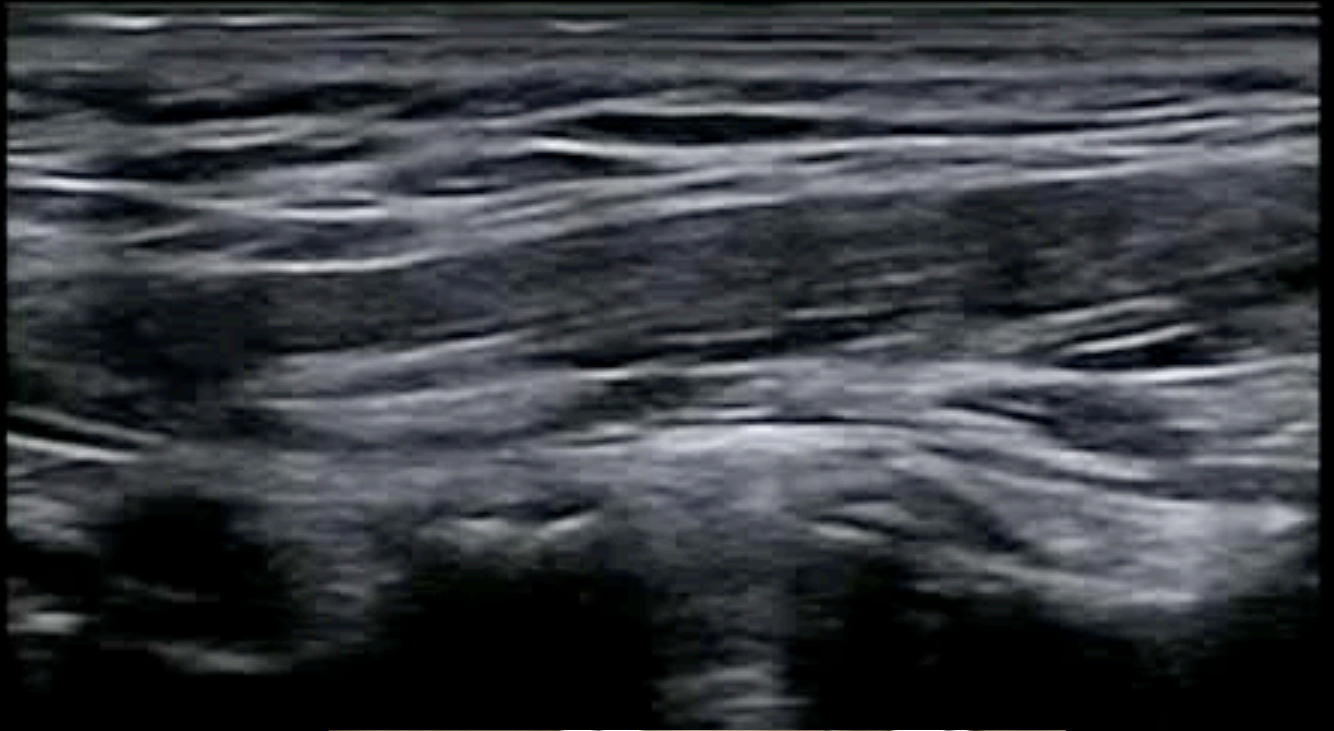
Infiltration 3 mal PRP

→ Anhaltend besser

Manuelle und aktive Therapie wieder möglich
(Übungen im HP, Haltungsverbesserung etc.)





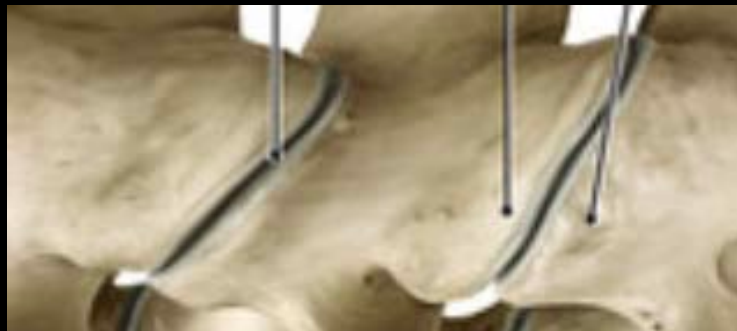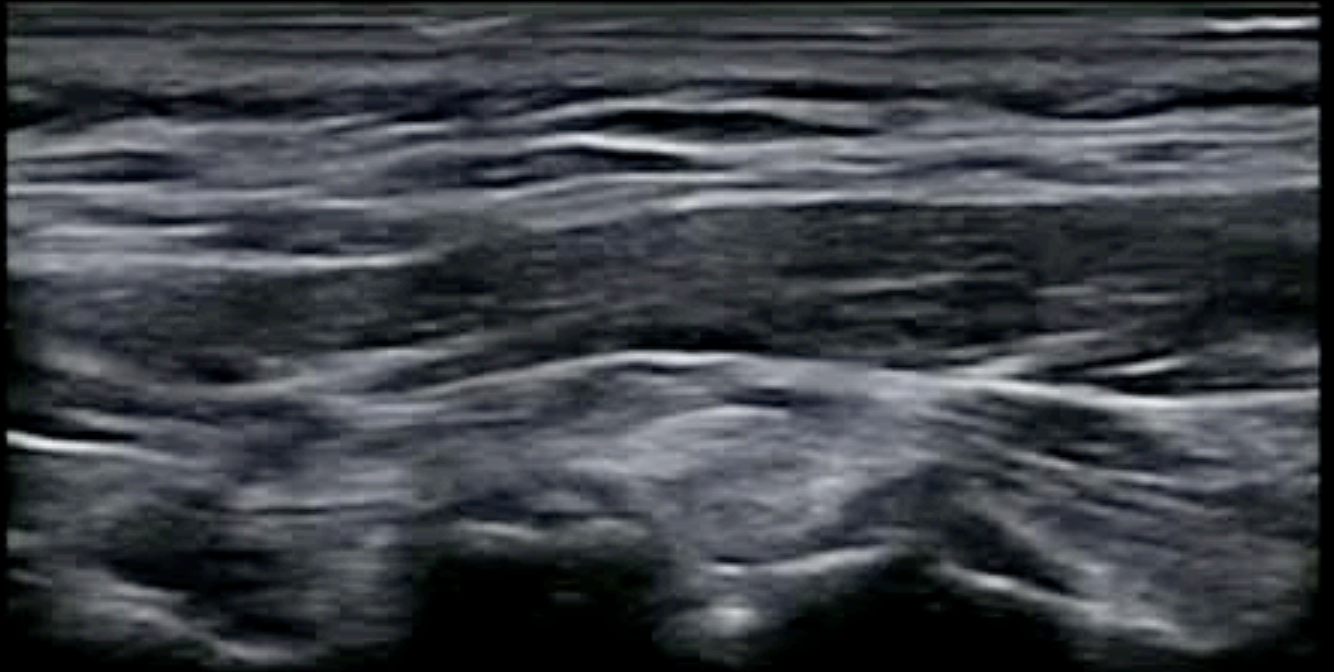


0

1

2

3




0

1

2

3



**PRP-Therapy
in the Treatment of
Spine Problems**

**Case Report 2
Costovertebral Joint
Injection**

Fall 2

24j Leistungsschwimmerin

ZW HA bei thorakalen Sz > 4 Mt.

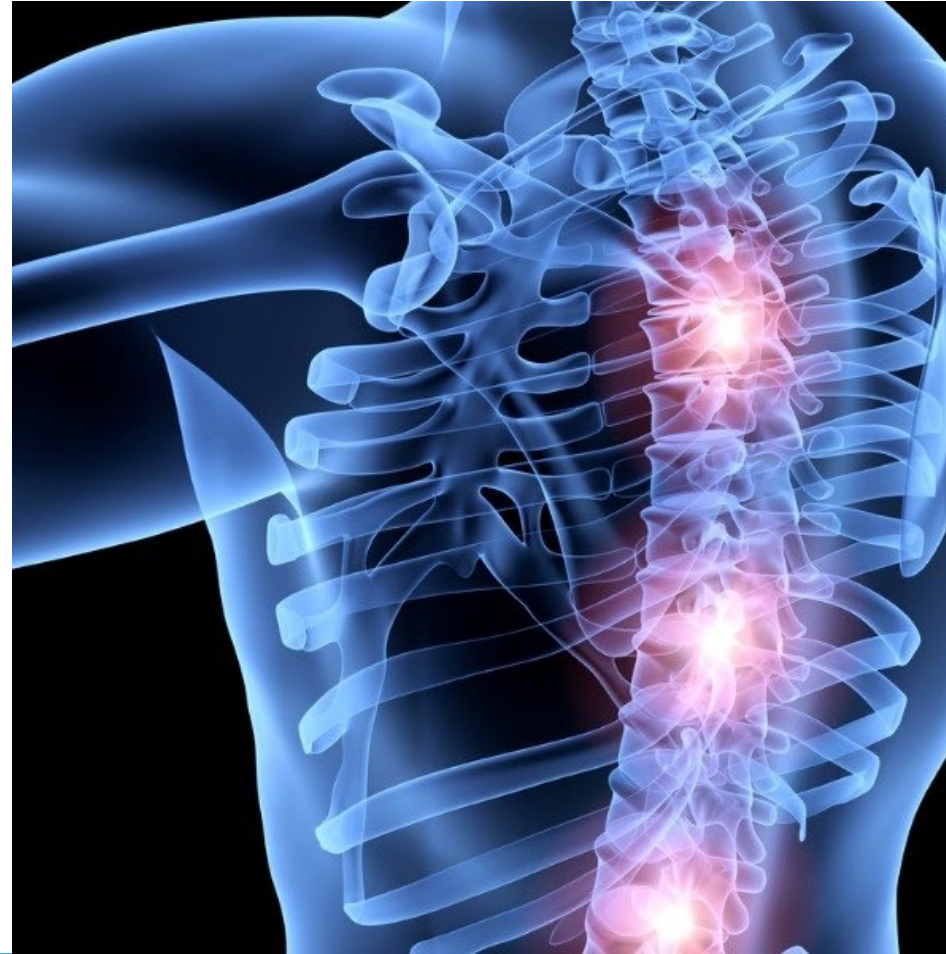NSAR und PT, (Versuch Chiropraktor,
Blackroll)

Rö und MRI unauffällig

Musk-Sportl. Habitus, keine Fehlhaltung
oder Haltungsinsuffizienz

Sz bei Bel, tw. in Ruhe, Insp.

MM: DS Th3 bis Th5 re > li



Fall 2

24j Leistungsschwimmerin

ZW HA bei thorakalen Sz > 4 Mt.

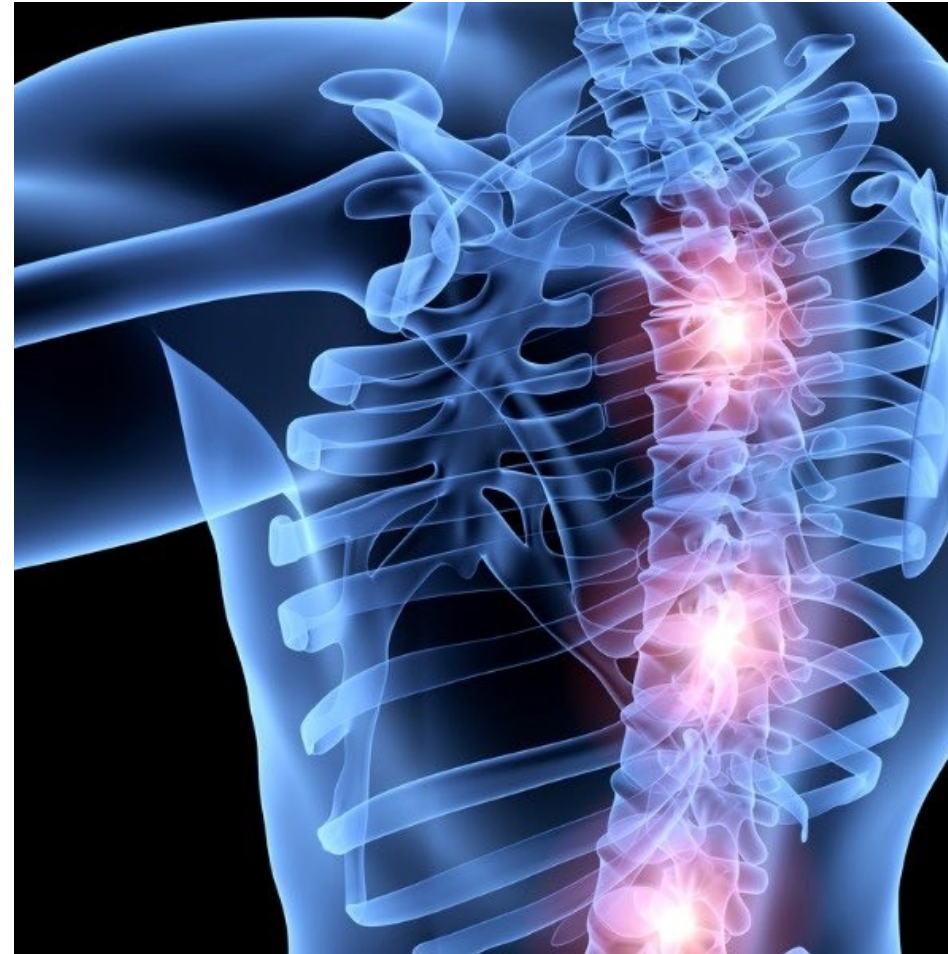NSAR gestoppt, PT weiter

3x PRP Th3 bis Th5 bds.

follow-up: Besserung nach 2-4 Wo

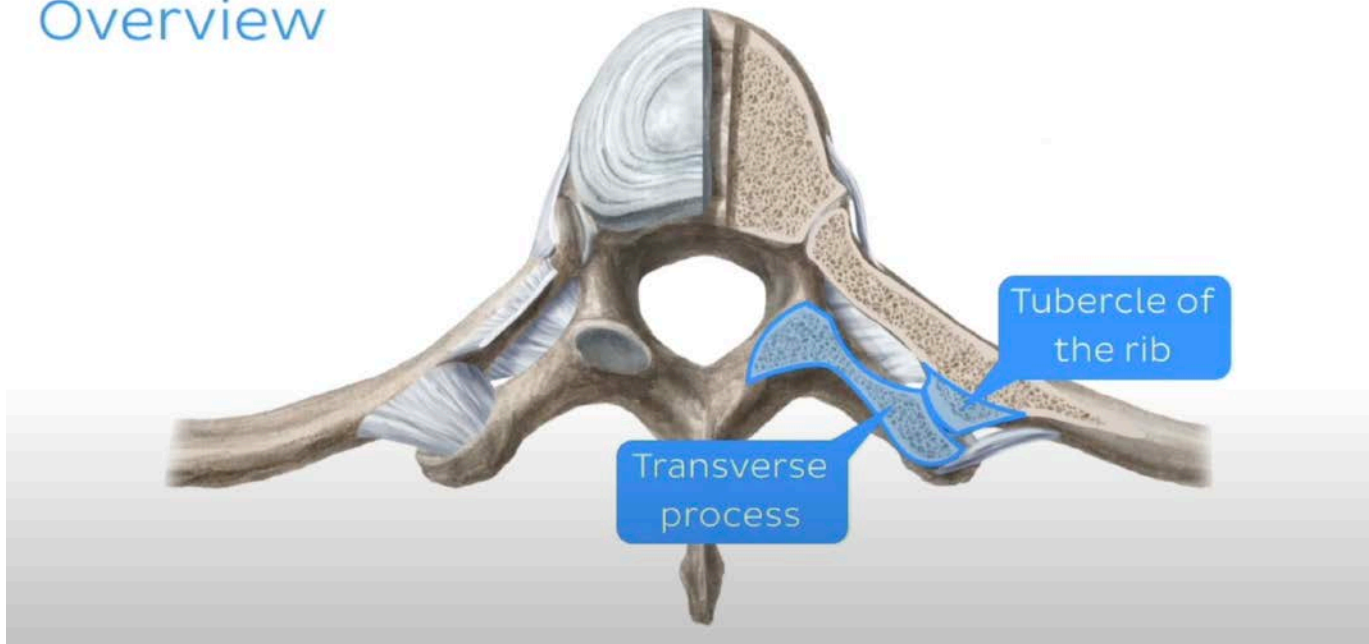
volle Trainingsintensität möglich

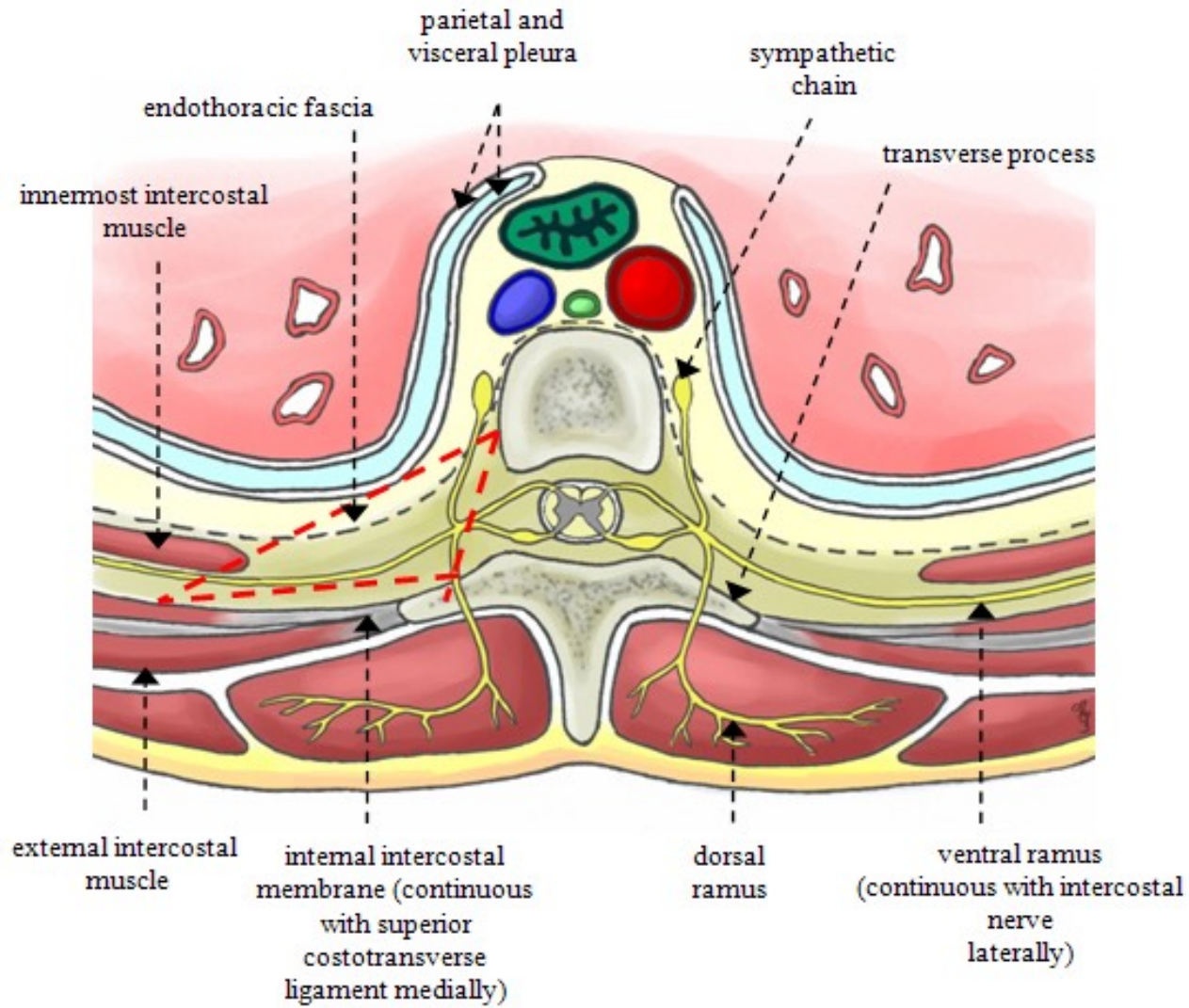
bei Rezidiv nach 4 Mt. re 2. Serie re

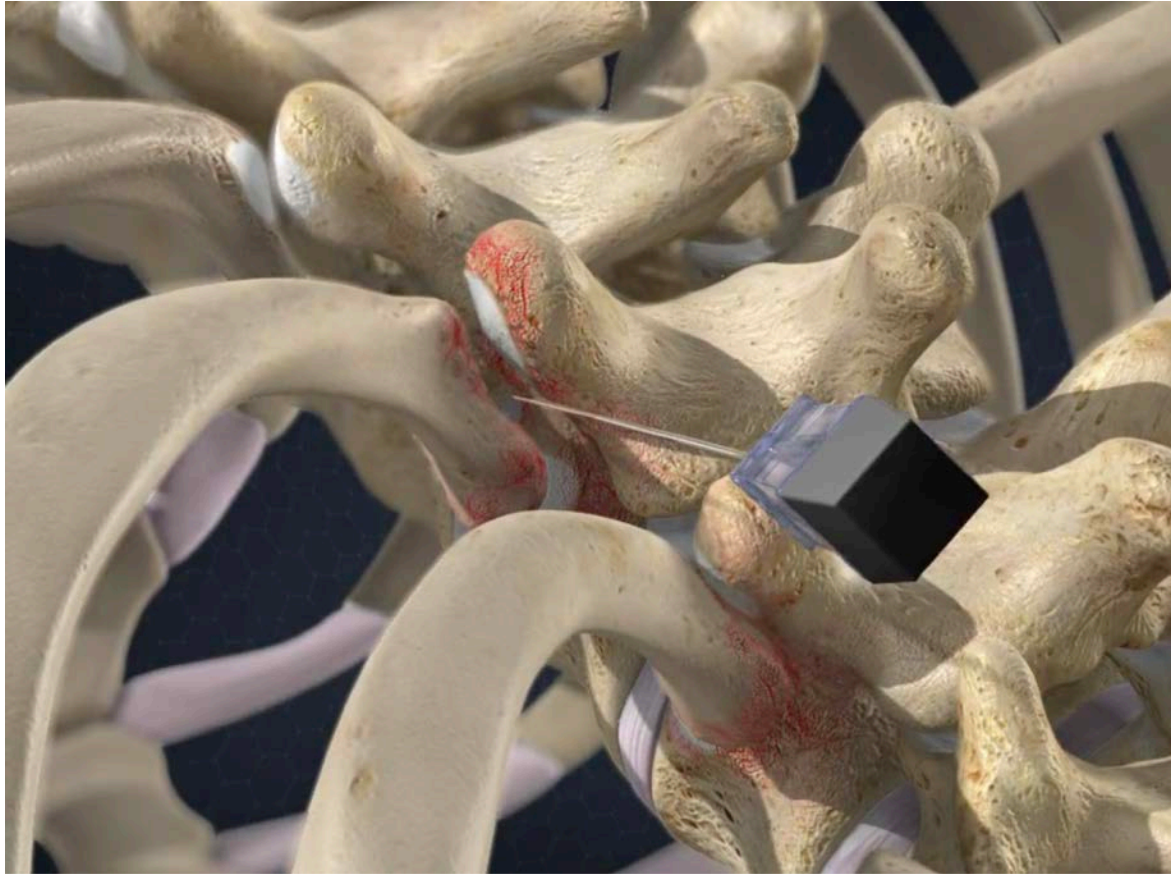

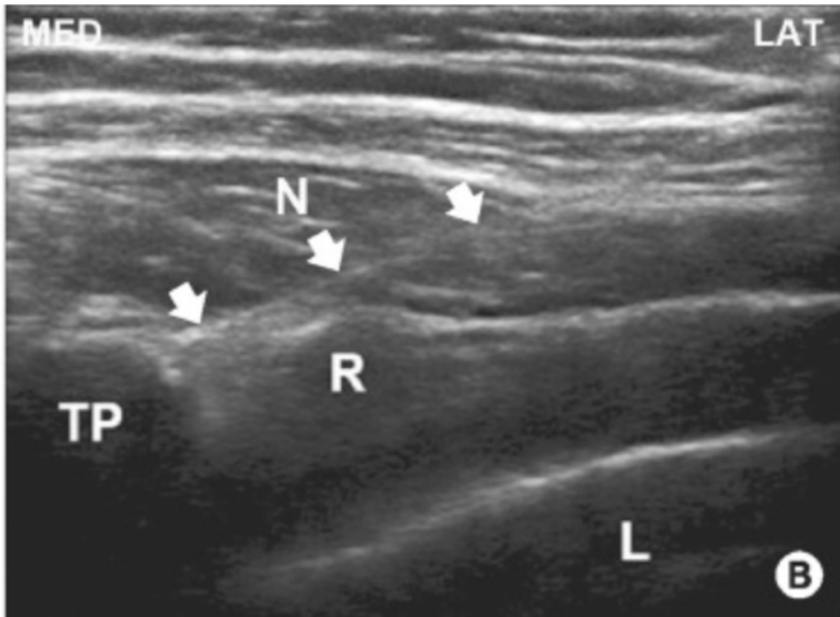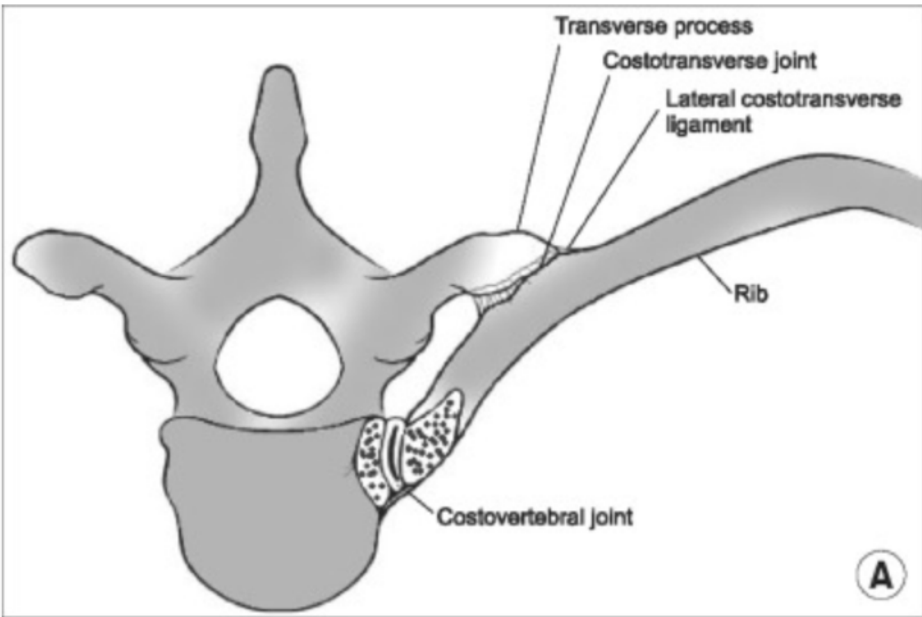
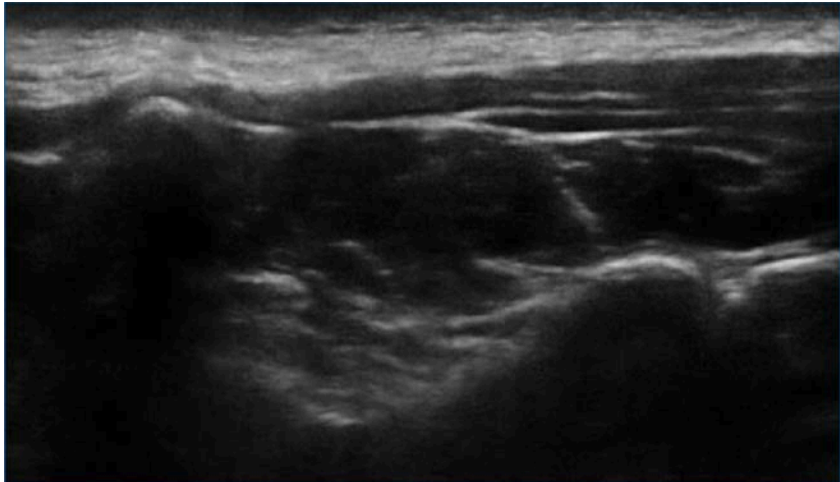
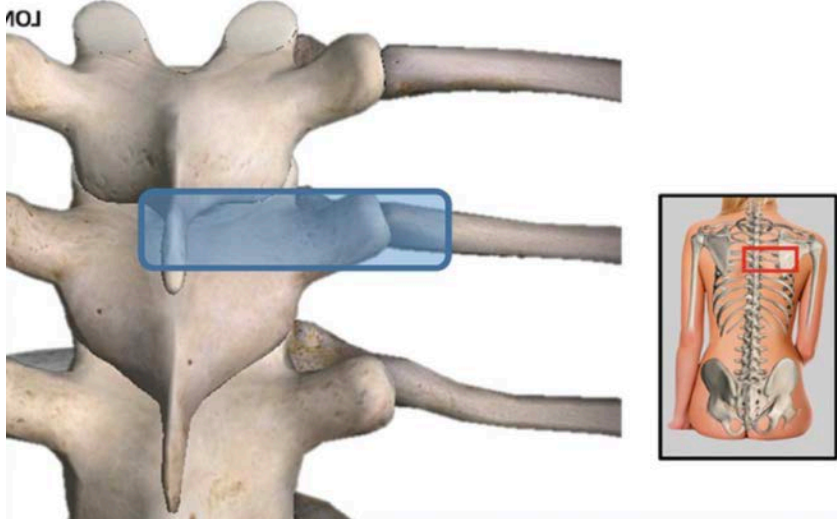
Costovertebral Joint Injection

Overview









PRP — Teil einer multimodalen Therapie

Therapie der Ursache?

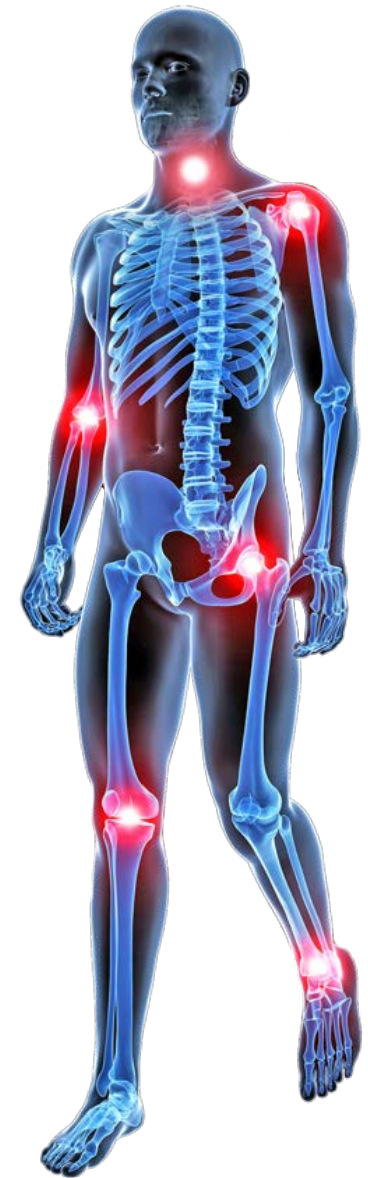Physiotherapie mit primär aktiven Massnahmen
im Heimprogramm

z.B. Haltungsverbesserung, Ergonomie,
Muskelaufbau und verbesserte Stabilisierung
(Rumpf, Schultergürtel, Beinachsen...), Dehnen,
Traktion etc.

Manuelle Therapie

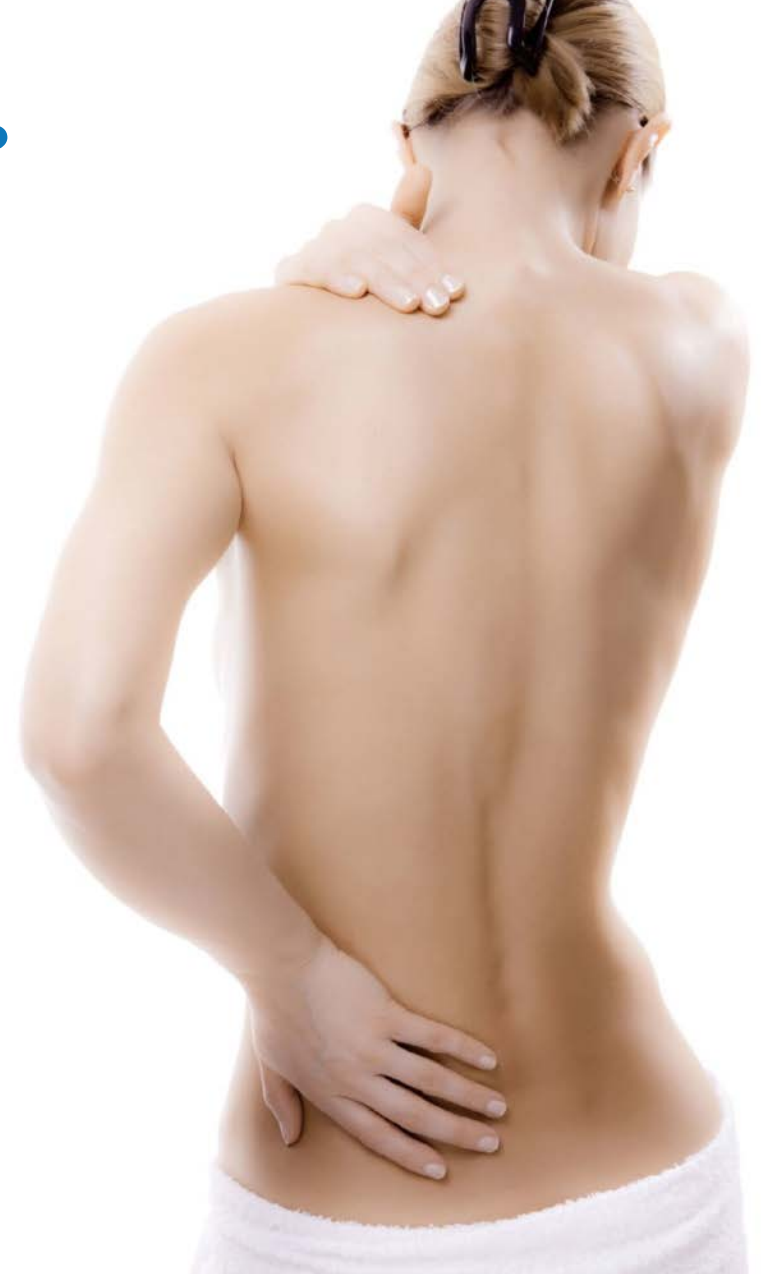Gewichtsreduktion, Ernährung

Psychotherapie



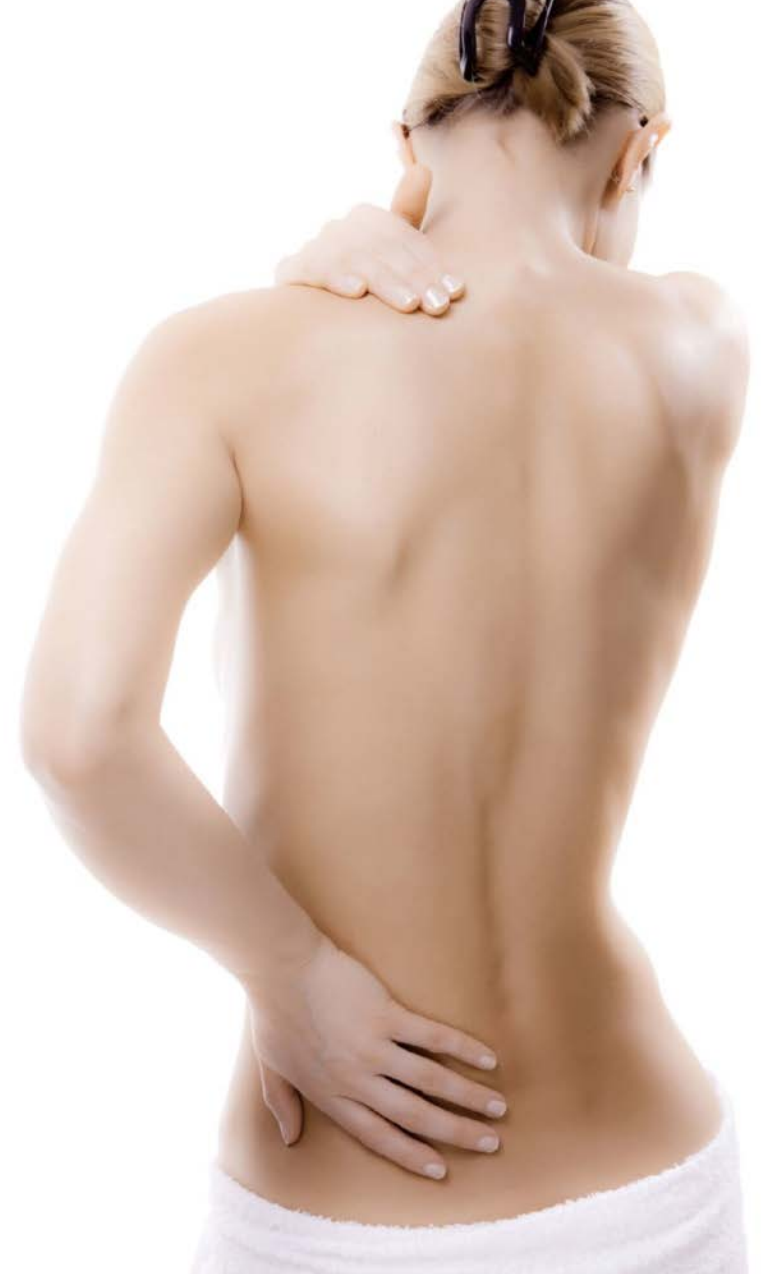PRP Therapie - Disadvantages?

- Triple Serie
- Possible pain after injection
- Missing diagnostic Value
- Compliance?
- Costs for the Patient
- As strong as the self-healing power
- Weaker in older patients or in smokers
- Weak when mixed with LA, NSA, Steroids



PRP Therapy - Take Home

- Enhance soft tissue healing
 - Faster regeneration time
 - Pain reduction
 - Improved function
- Safe and easy
- Evidence based
- Treatment of choice for many indication
 - Akute and chronic
 - Joints, Tendons, ligaments, nerves, discus
- Disadvantages need to be considered
- Thrombozytenreiches Plasma und manuelle Medizin — eine Symbiose





Danke!

...haben Sie Fragen?



Vielen Dank!

Dr. med. Moritz Dau
ortholink.ch

Orthopädie
am Rhy



BIOGENERATIVE

BEHANDLUNGSMETHODE

Anwendung von
thrombozytenreichem
Plasma PRP
an der Wirbelsäule

DR. MED. MORITZ DAU
PRAXIS ORTHOPÄDIE AM RHY
RHEINFELDEN, SCHWEIZ

Wirbelsäulenbeschwerden sind bei Sportlern in nahezu allen Sportarten ein sehr häufiger Grund für eine Einschränkung der Sportfähigkeit. In der Sportmedizin des Bewegungsapparates nimmt daher die Auseinandersetzung mit der Wirbelsäule einen hohen Stellenwert ein. Die Anwendung von PRP (platelet-rich plasma) als therapeutische Maßnahme für Erkrankungen am Bewegungsapparat ist bereits breit etabliert. Zunehmend findet PRP Einzug als erfolversprechende minimalinvasive Behandlungsalternative an der Wirbelsäule.

Genauso wie am ganzen Bewegungsapparat spielen auch hier chronisch-entzündliche und degenerative Veränderungen als Ursache von relevanten Beschwerden eine entscheidende Rolle. In der mittlerweile umfangreichen Literatur findet sich eine hohe Evidenz für Behandlungen von Arthrosen (z. B. Gonarthrose), [1, 2] Tendinosen (z. B. Tennisellenbogen, Jumpers knee, Achillodynien) und Ligamentosen [3–6]. Grundsätzlich ähnliche Strukturen und entsprechende pathologische Veränderungen spielen auch bei Erkrankungen an der Wirbelsäule eine entscheidende Rolle. Zu den Hauptursachen von Beschwerden an der Wirbelsäule gehört die



Thank You!

...any questions?