


Entrapment Neuropathie am Becken: Was ist objektivierbar?

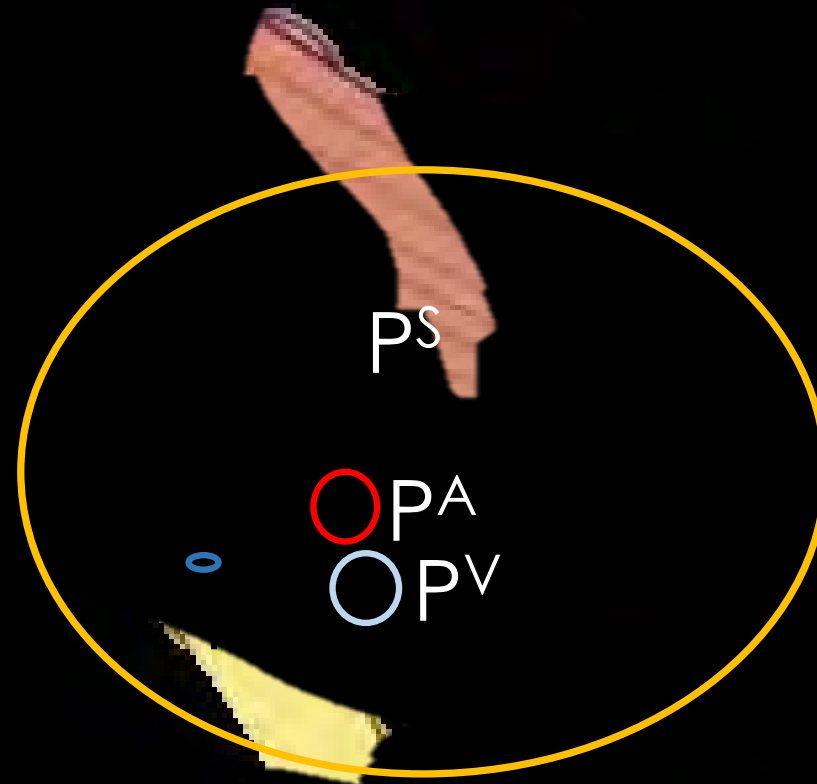
www.neuro-research.ch

A/Prof Annina Schmid





Umkehr des Druck Gradienten

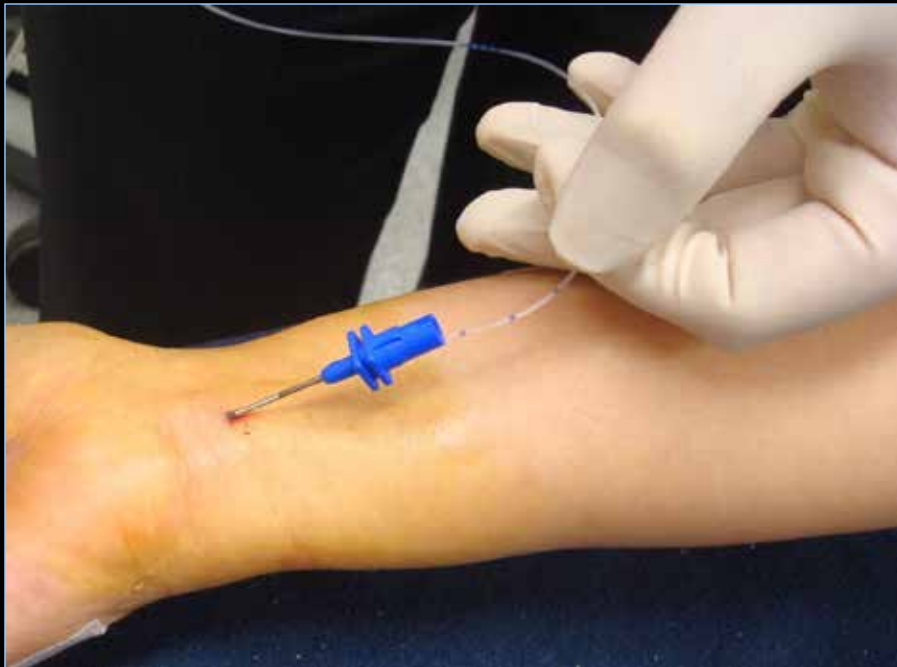

Arterie>Kapillare>Nervfaszikel>Vene>umgebenes Gewebe

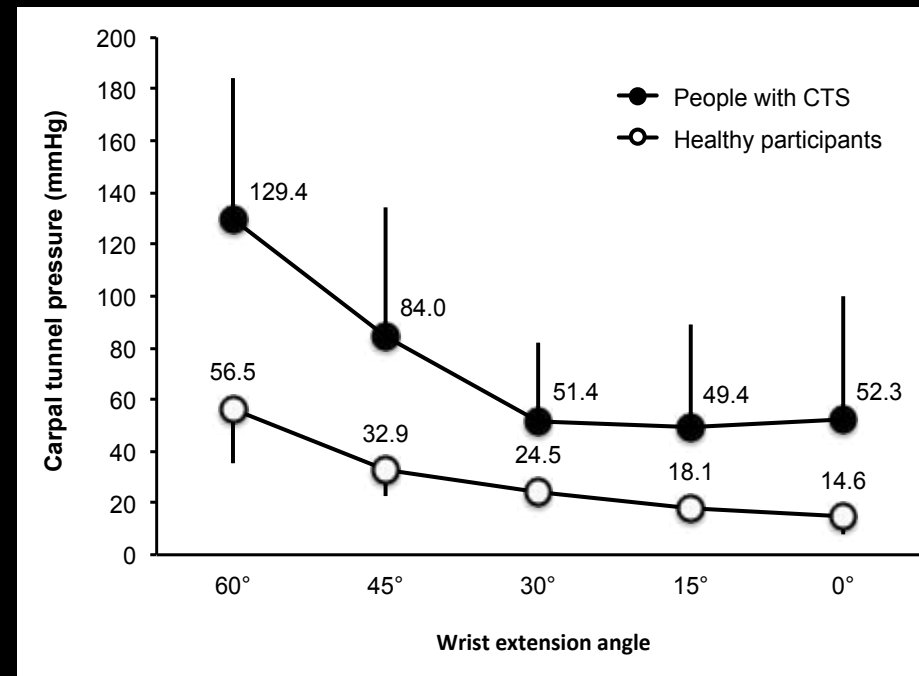
Sunderland 1976

Umkehr des Druck Gradienten

Epidural Katheter



Karpal Tunnel Druck

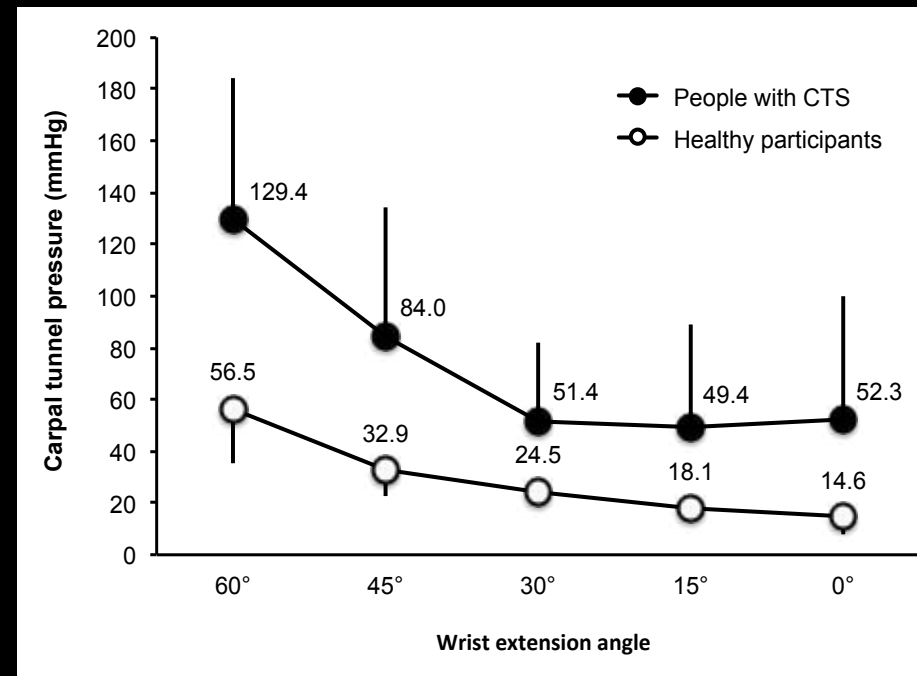


Umkehr des Druck Gradienten

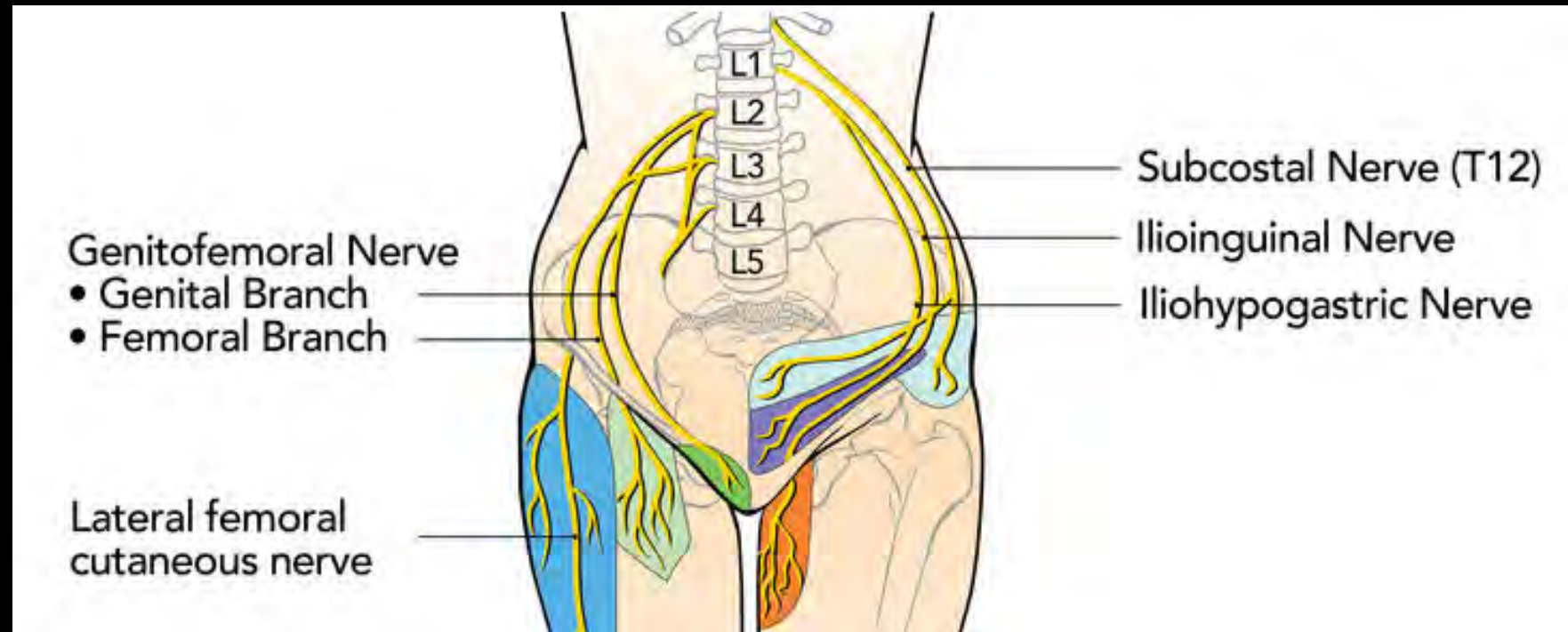
Tibialis anterior

- Ruhe: 0-20mmHg
- Joggen: 23-66mmHg

Karpal Tunnel Druck



Beckenregion

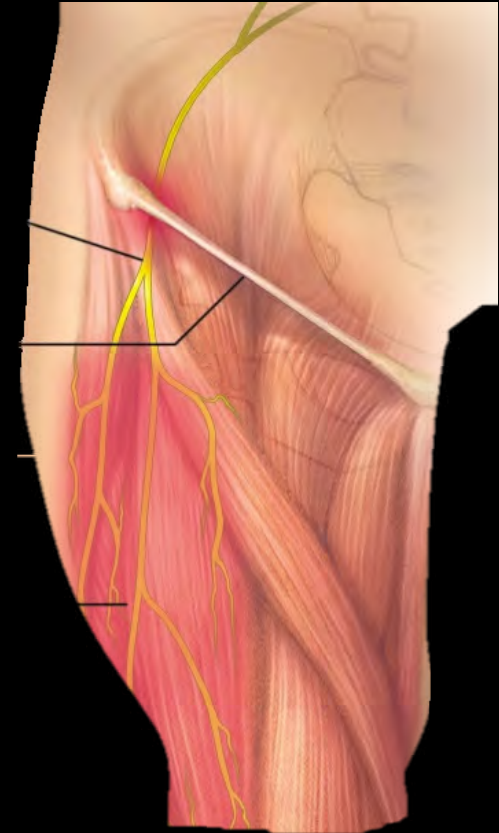


Meralgia Paraesthetica

N. Femoralis lateralis cutaneus

Incidence:
24.2/100'000

CTS:
172/100'000

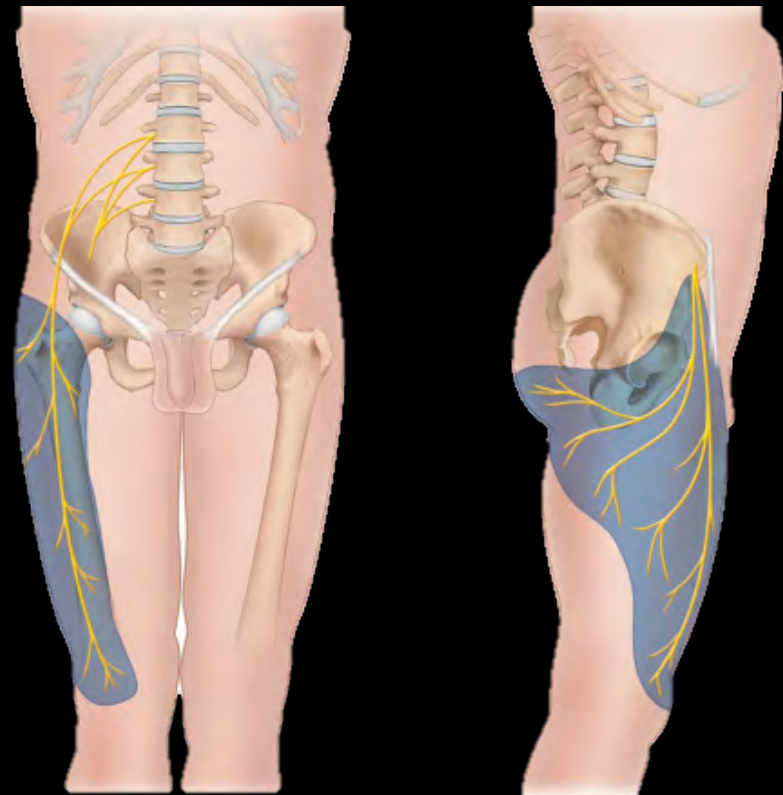


Klinische Praesentation

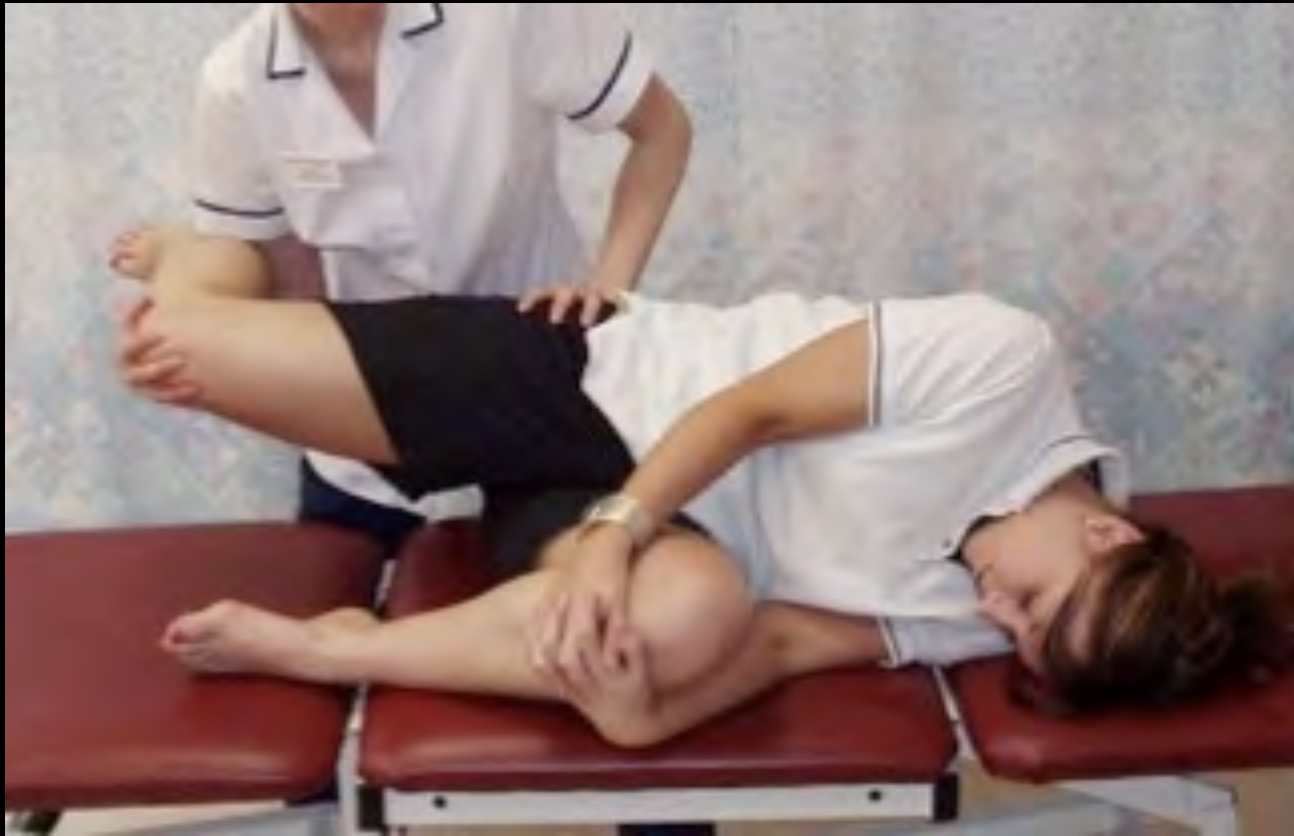- Maenner>Frauen
- 54 Jahre
- Taubheit
- Brennende Schmerzen
- Kribbeln

Zeichen:

- Hypoaesthesie

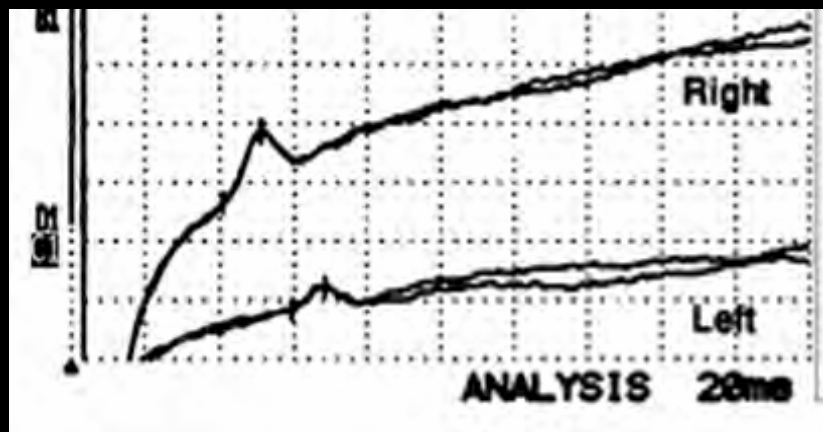


N. Femoralis slump



Neurologie objektivierbar?

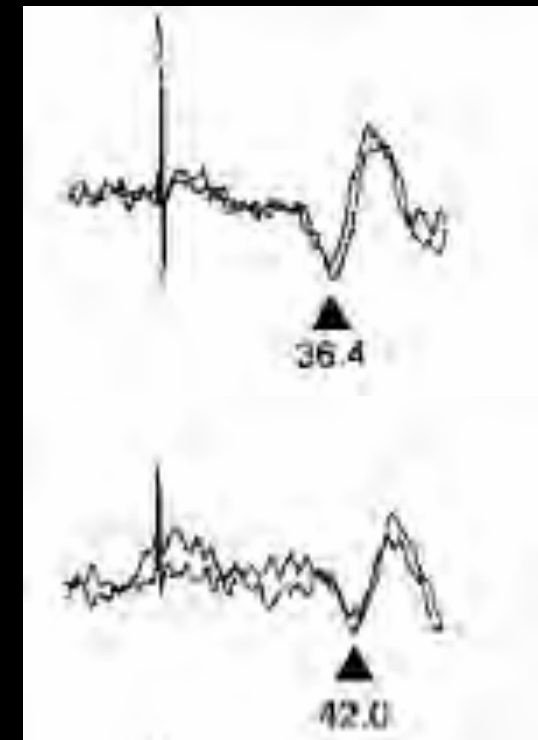
Nervenleitfähigkeit, sensorisch
(65%)



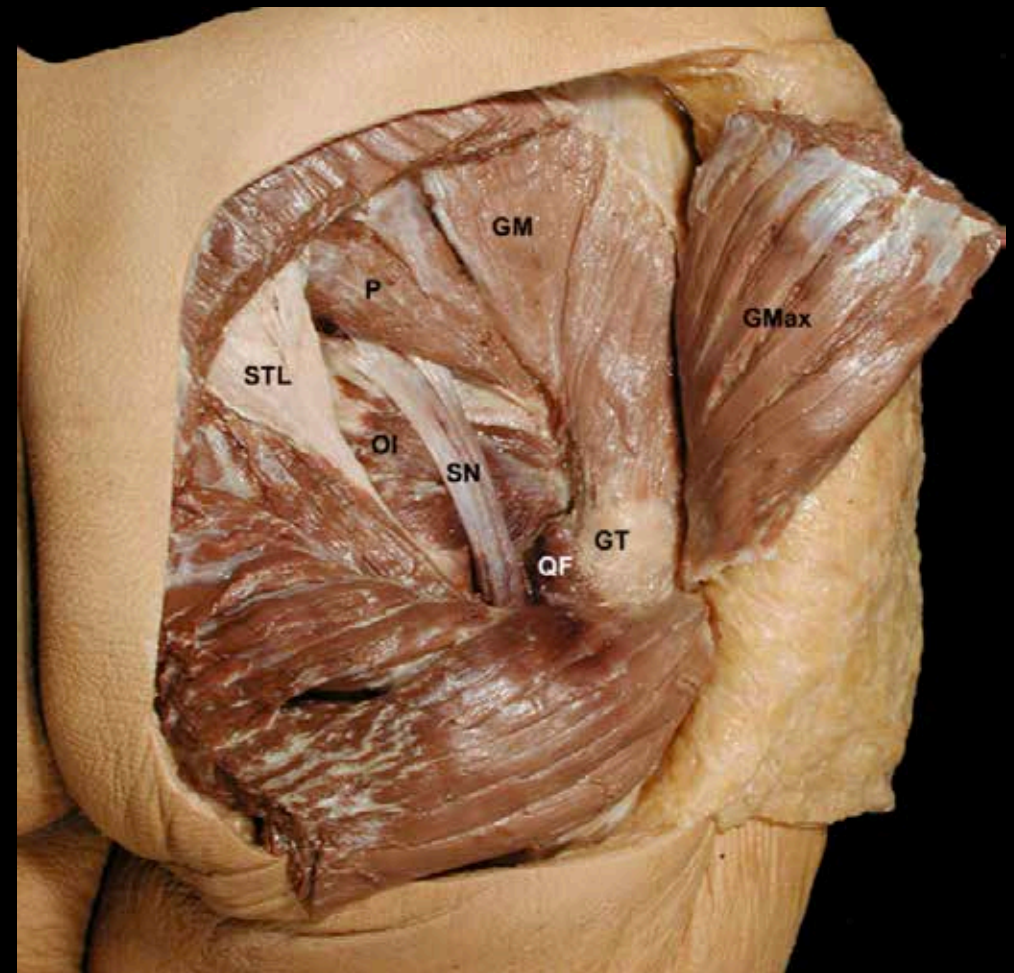
Betroffen

Nicht betroffen

Somatosensorisch evoziertes
Potential (81%)



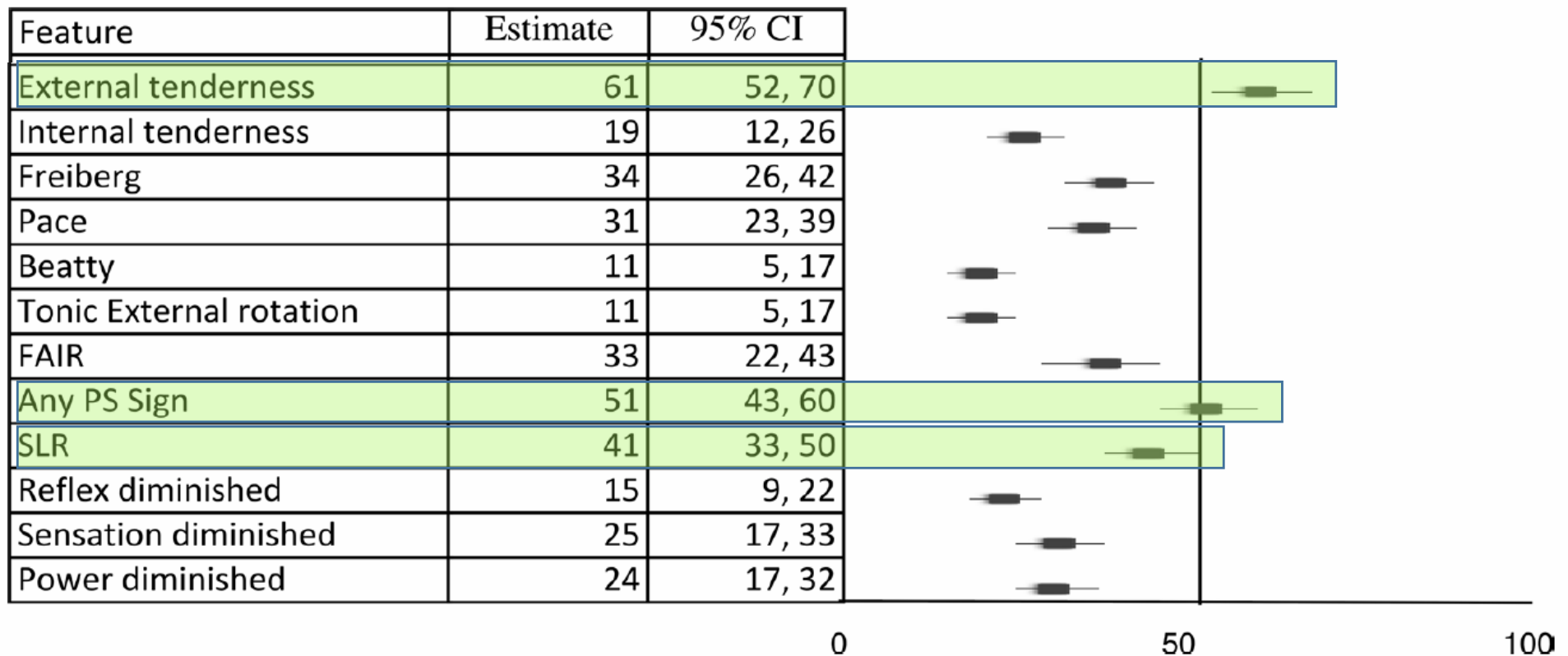
Piriformis Syndrom



Subjektive Symptome (case studies)

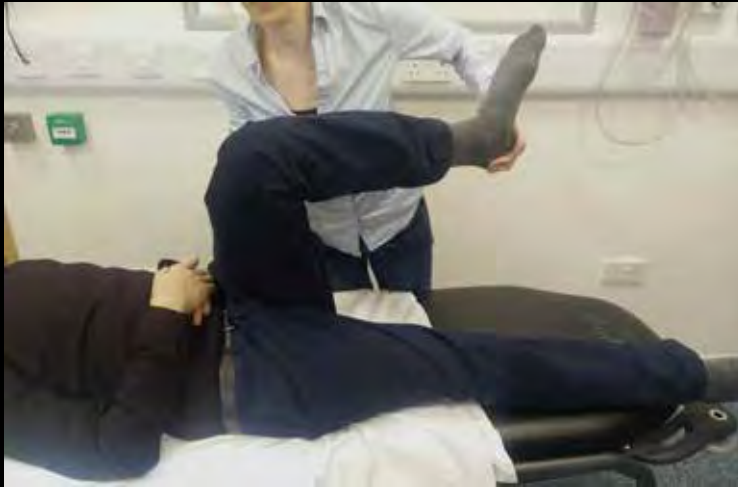Feature	Estimate	95% CI	
Buttock pain	56	47, 65	
Low back pain	26	18, 33	
Radiation leg	77	70, 85	
Difficulty sitting	40	32, 49	
Paraesthesia	31	23, 39	
Dyspareunia	23	7, 40	

Objektive Zeichen (case studies)

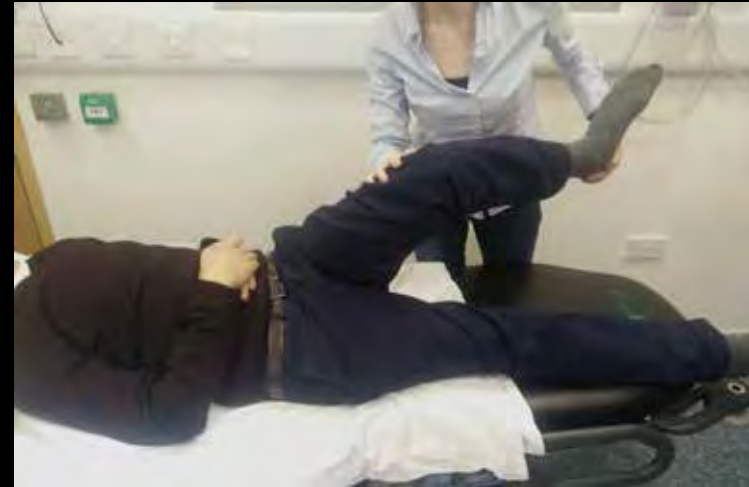

Piriformis Syndrom Tests

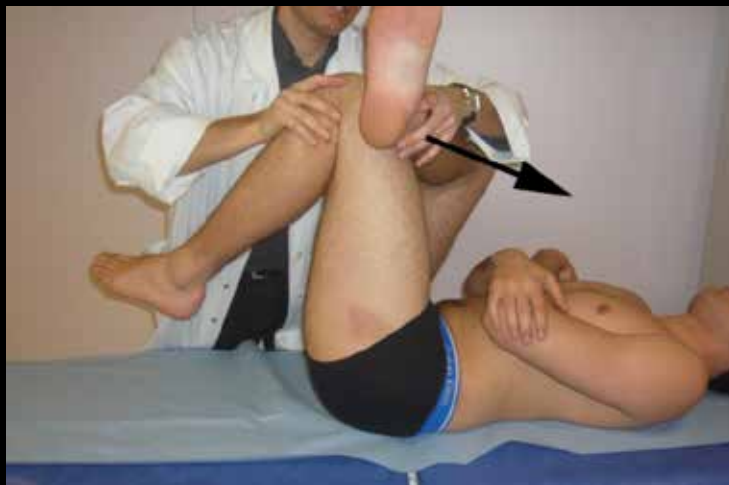FAIR (Flex/Add/IRot): 93%



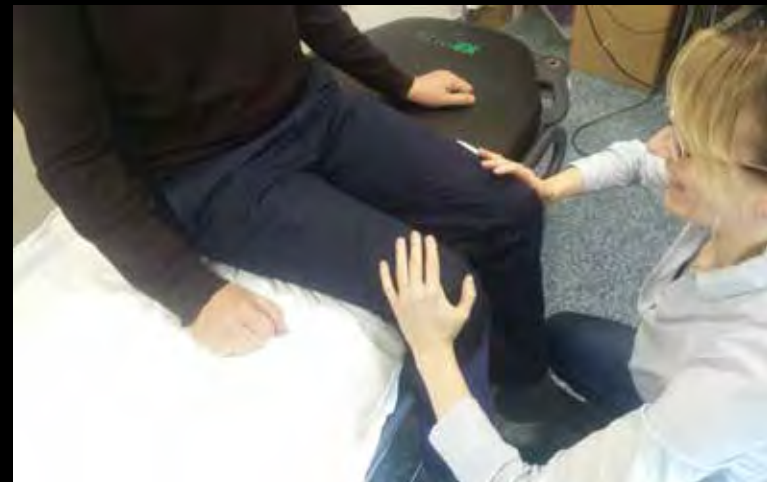Feinberg: 84%



Heel contralateral knee (HCLK)



PACE: 55%



Diagnostische Kriterien (n=250)

Unilaterale or bilaterale Gesaess Schmerzen, intermittierend	1
Ausstrahlende Beinschmerzen, intermittierend	1
Keine Rueckenschmerzen	1
Keine perianale Ausstrahlung	1
Verstaerkte Schmerzen im Sitzen (Gesaess und/oder Bein)	1
Axiale spinale Palpation schmerzfrei (L2 -S1)	1
Negativer Lasegue	1
Gesaess Schmerzen ausgeloeost durch:	
Stretching (FAIR, Freiberg, HCLK)	1
Kontraktion(Beatty)	1
Palpation	1
Beinschmerzen ausgeloeost durch:	
Stretching	1
Kontraktion	1

≥8: Piriformis Syndrom moeglich
Sensitivitaet: 96.4%; Spezifitaet: 100%

Neurologie objektivierbar?

- Neurologische Defizits in $<2\%$ (Singh 2013)
- Nadel EMG unauffaellig in 100% (Michel 2013)
- H-Reflex in FAIR Position: verlangsamt in 18% (Michel 2013)

Warum so 'unobjektivierbar'?

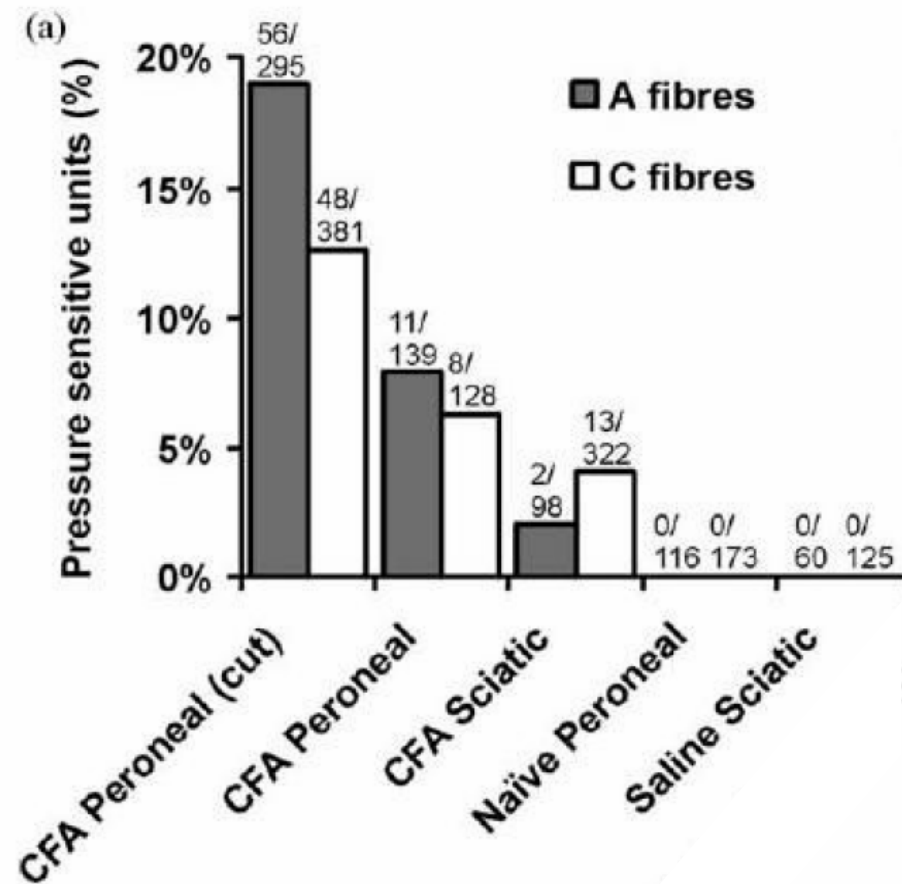
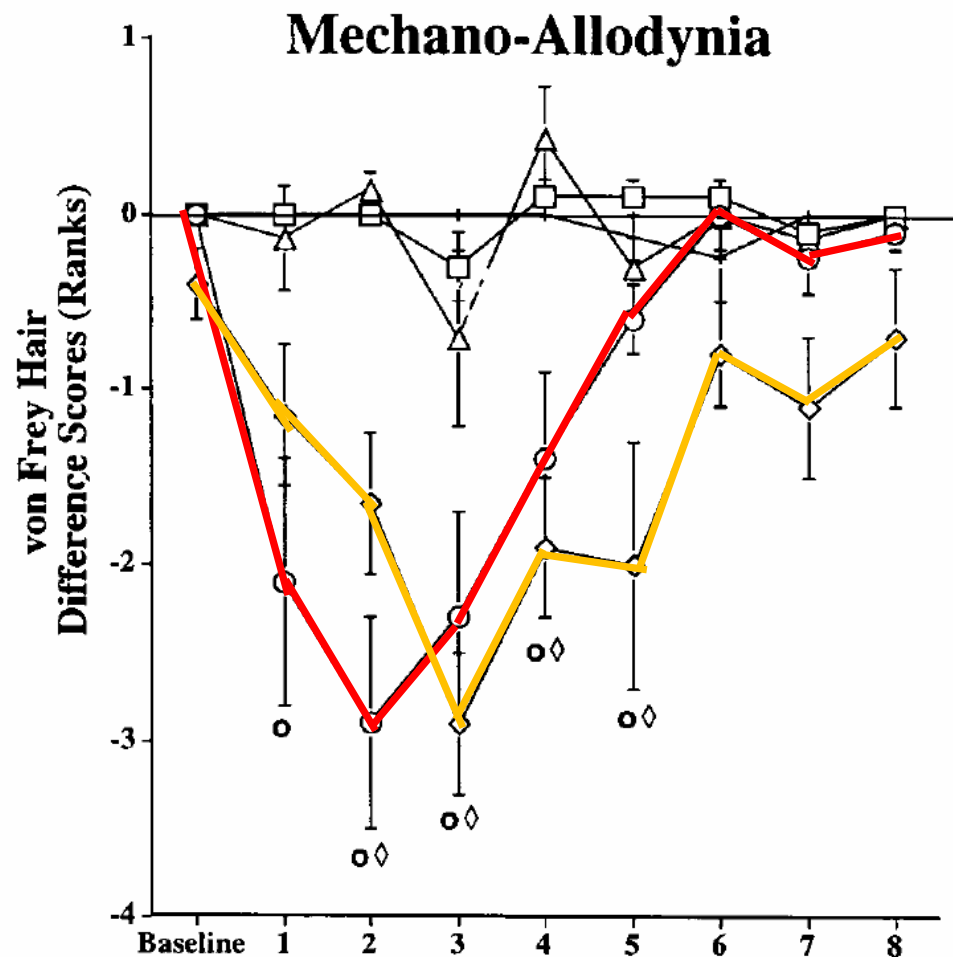


- Taubheit
- ↓ Kraft
- ↓ Reflexe
- ↓ Nervenleitfähigkeit



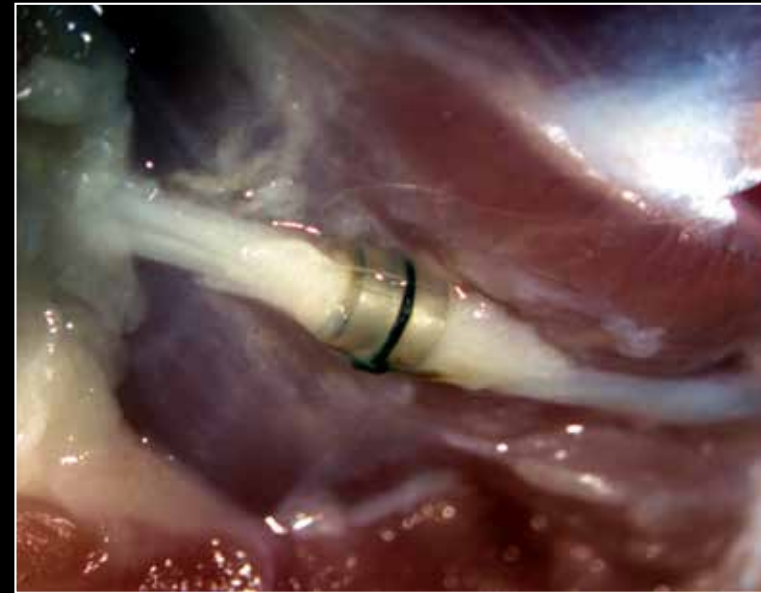
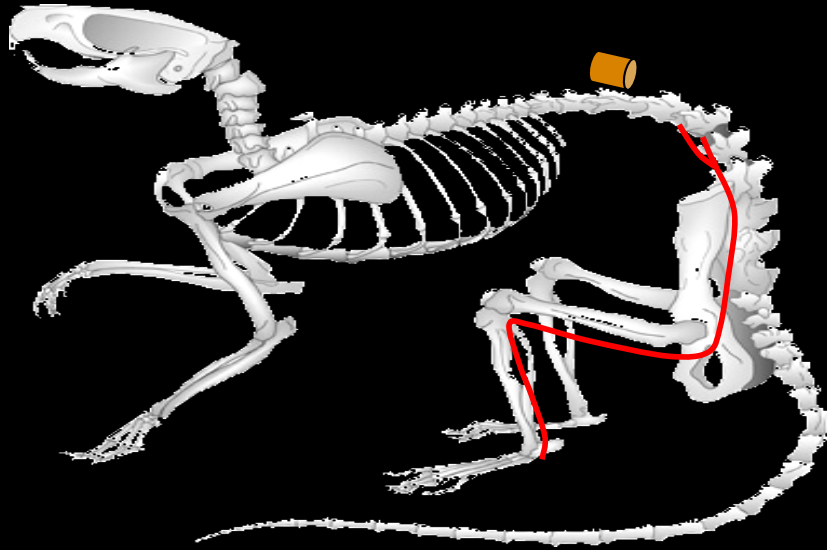
- Schmerz
- Paraesthesien
- Hypersensitivität
 - Allodynie
 - Hyperalgesie

Epineurale Entzündung



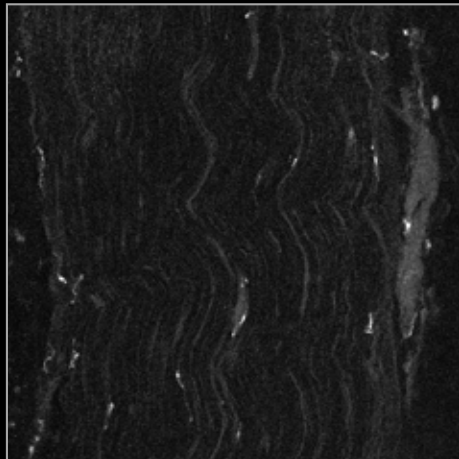
Tiermodell milde Nerven Kompression

- Silikon Roehrchen (McKinnon et al 1984, Gupta et al 2003)

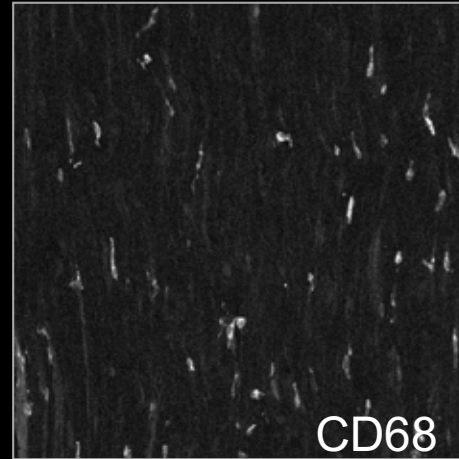


Intraneurale Entzündung

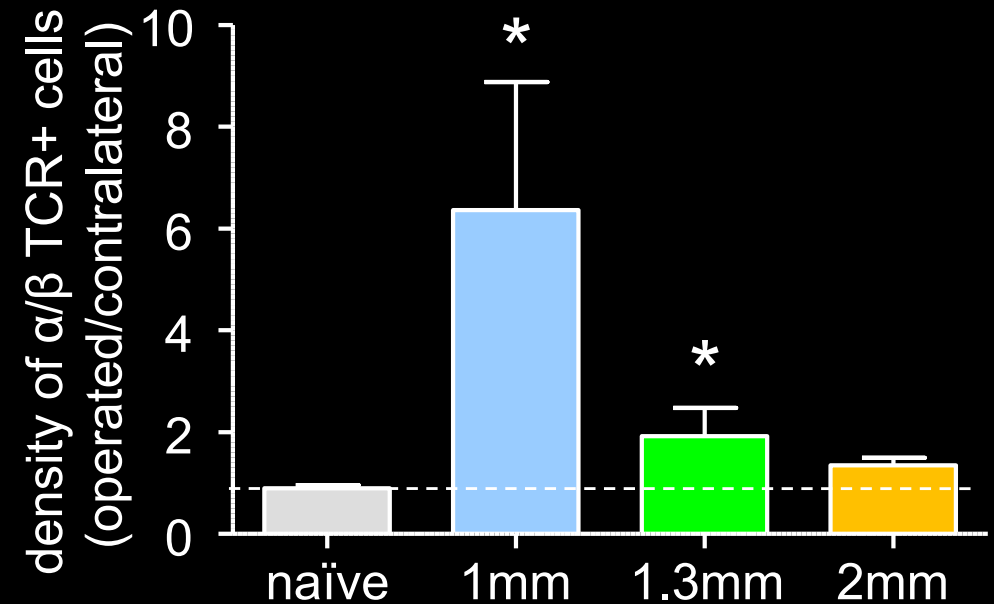
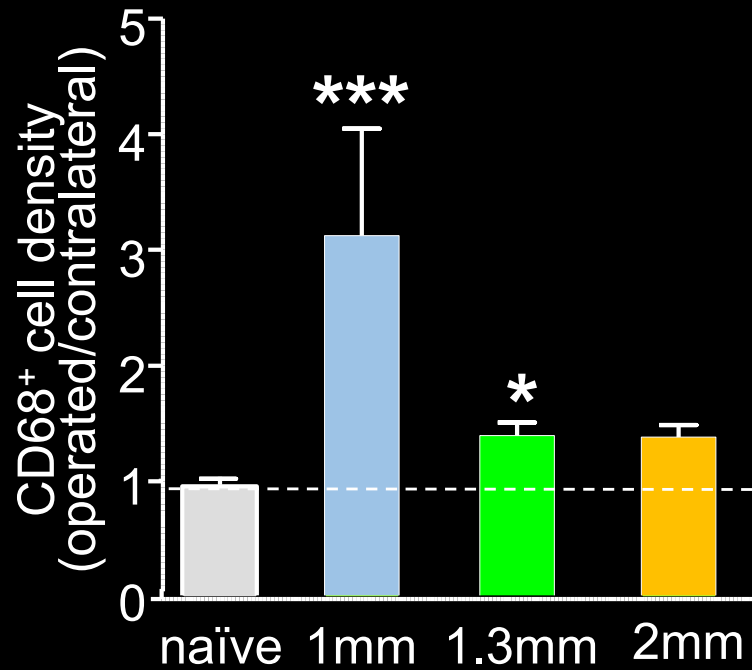
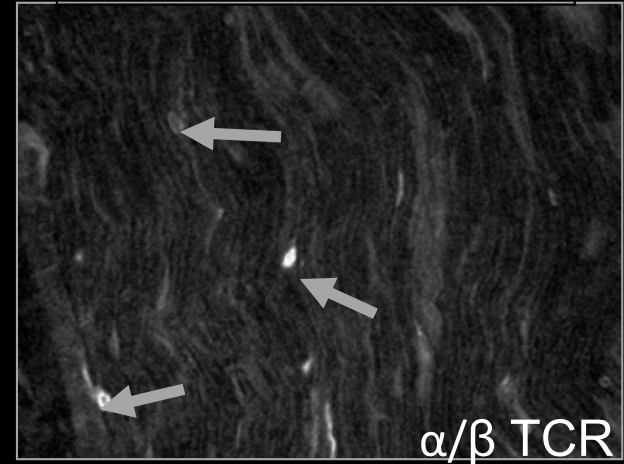
kontralateral



Kompression

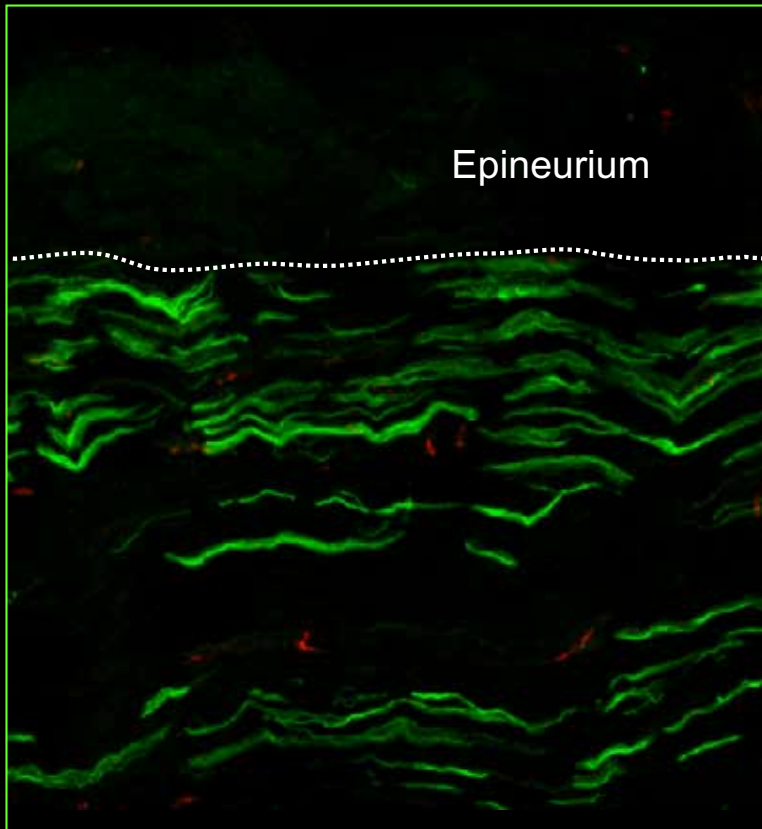


Kompression

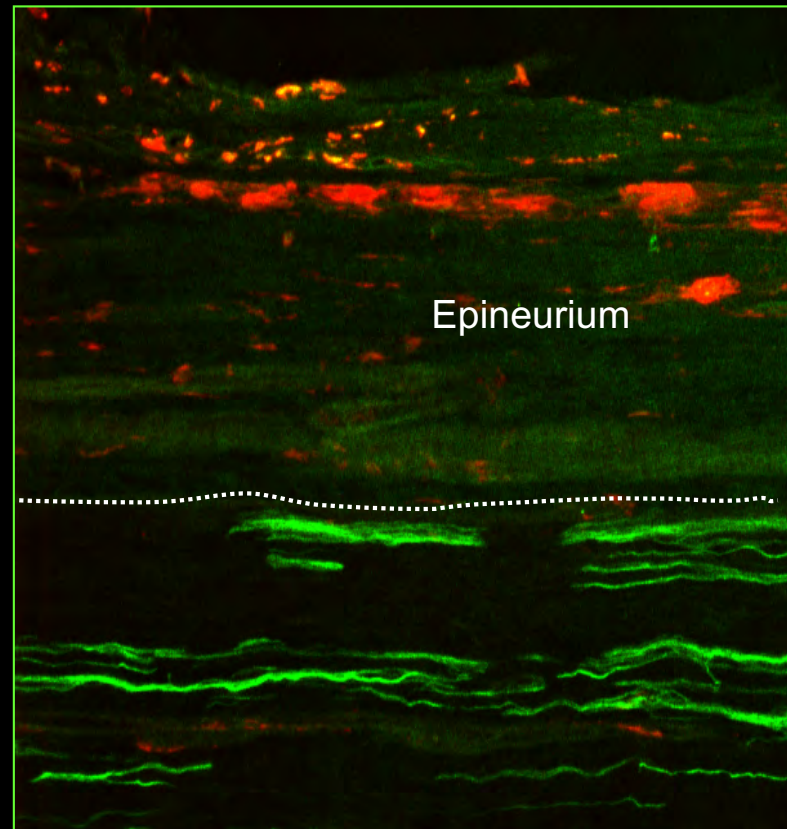


Epineurale Entzündung

kontralateral

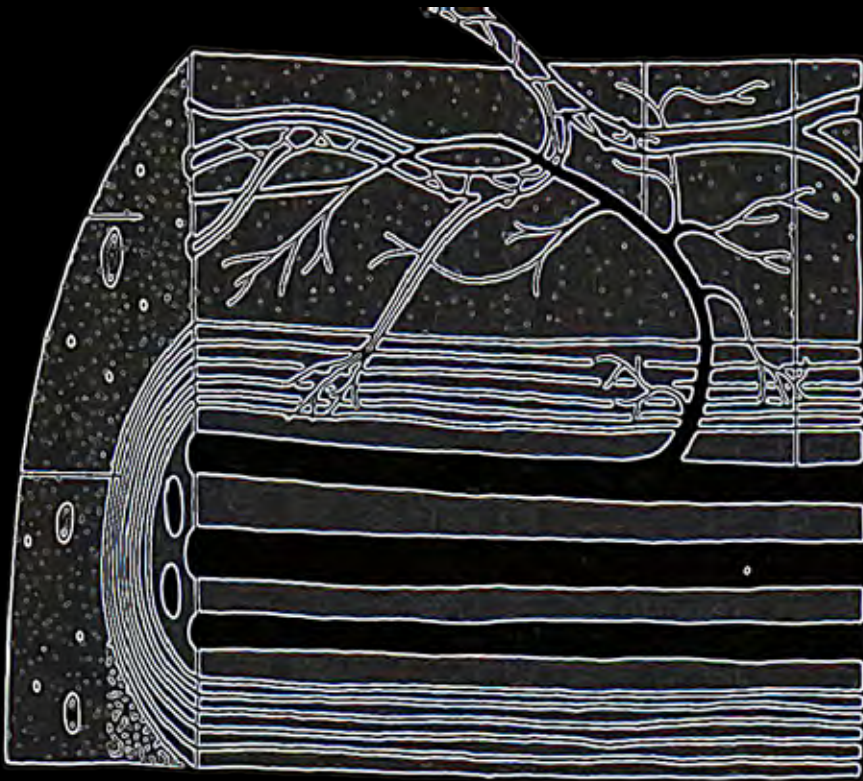


Kompression

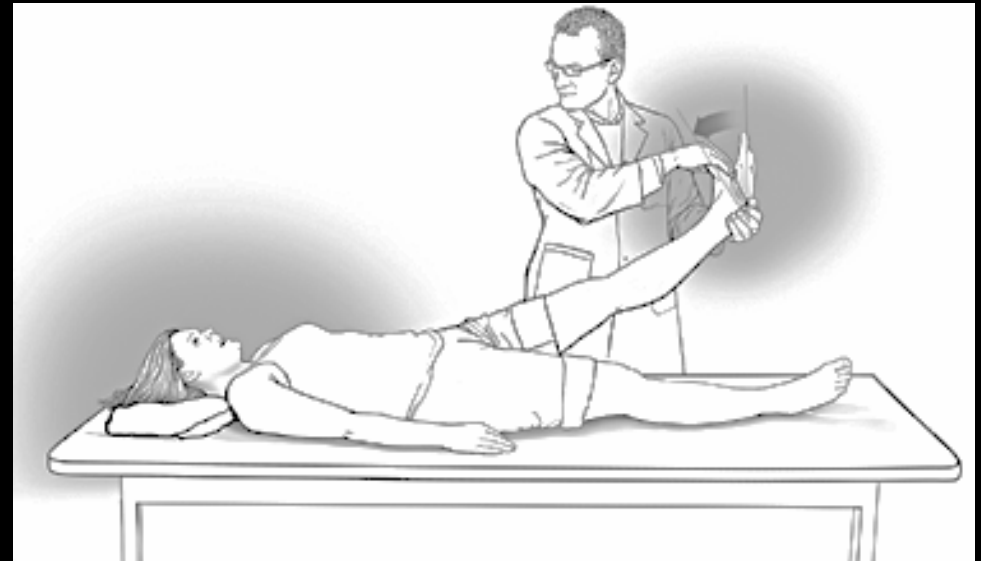


CD68+ Makrophagen GFAP

Nervi Nervorum



Hromada 1963



Zusammenfassung

- Entrapments am Becken sind moeglich...
- ...aber selten
- Schwierig objektivierbar
 - Gain of function
- Es bleibt eine Ausschlussdiagnose



Danke!

UK

- Prof David Bennett
- Prof Irene Tracey
- A/Prof D Furniss
- Prof Elspeth McLachlan
- Dr Robert Frost
- Dr Stuart Clare
- Dr Jeremy Bland
- Dr Colette Ridehalgh

Current and past students

- Oliver Sandy-Hindmarch
- Akira Wiberg
- Guan Cheng Zhu
- Katherine Windsor
- Karina Boettger
- Igor Rocha
- Karina Lewis
- Larissa Baselgia
- Henry Munyanduki

Australia

- Prof Paul Hodges
- Dr Marc Ruitenberg
- Dr Brigitte Tampin

Denmark

- Dr Pall Karlsson

Chile

- A/Prof Margarita Calvo

wellcometrust



FONDS NATIONAL SUISSE
SCHWEIZERISCHER NATIONALFONDS
FONDO NAZIONALE SVIZZERO
SWISS NATIONAL SCIENCE FOUNDATION



Australian Government
National Health and
Medical Research Council

N H M R C



**National Institute for
Health Research**

Oxford Biomedical Research Centre
Enabling translational research through partnership