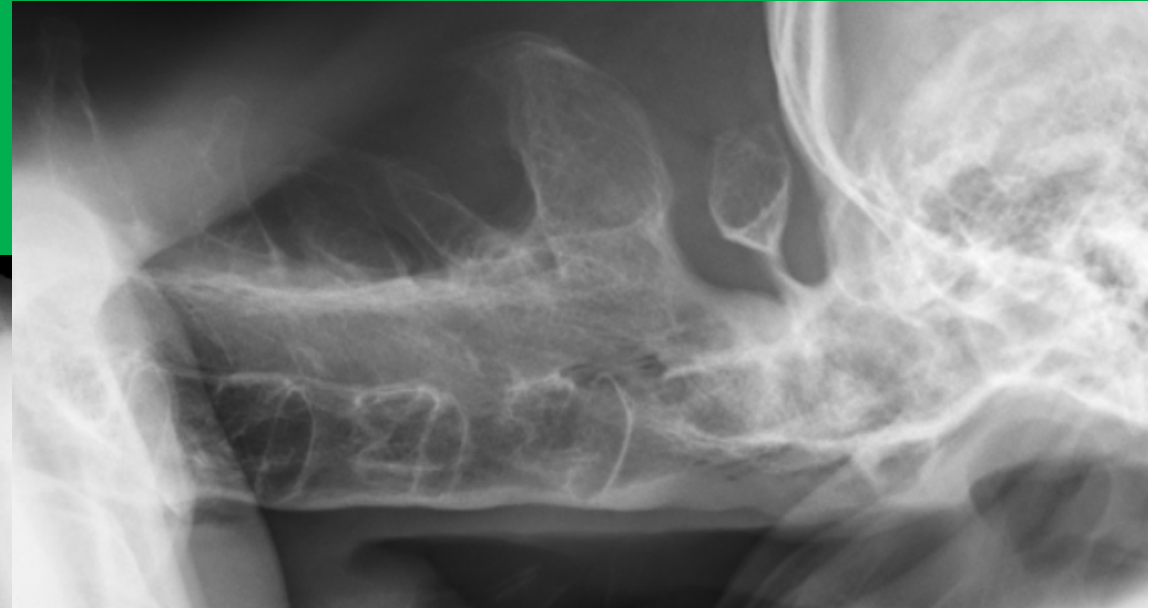




Update (seronegative) Spondyloarthritis

Prof. Peter M. Villiger

RIA Universitätsklinik für Rheumatologie, Immunologie und Allergologie
Inselspital Bern

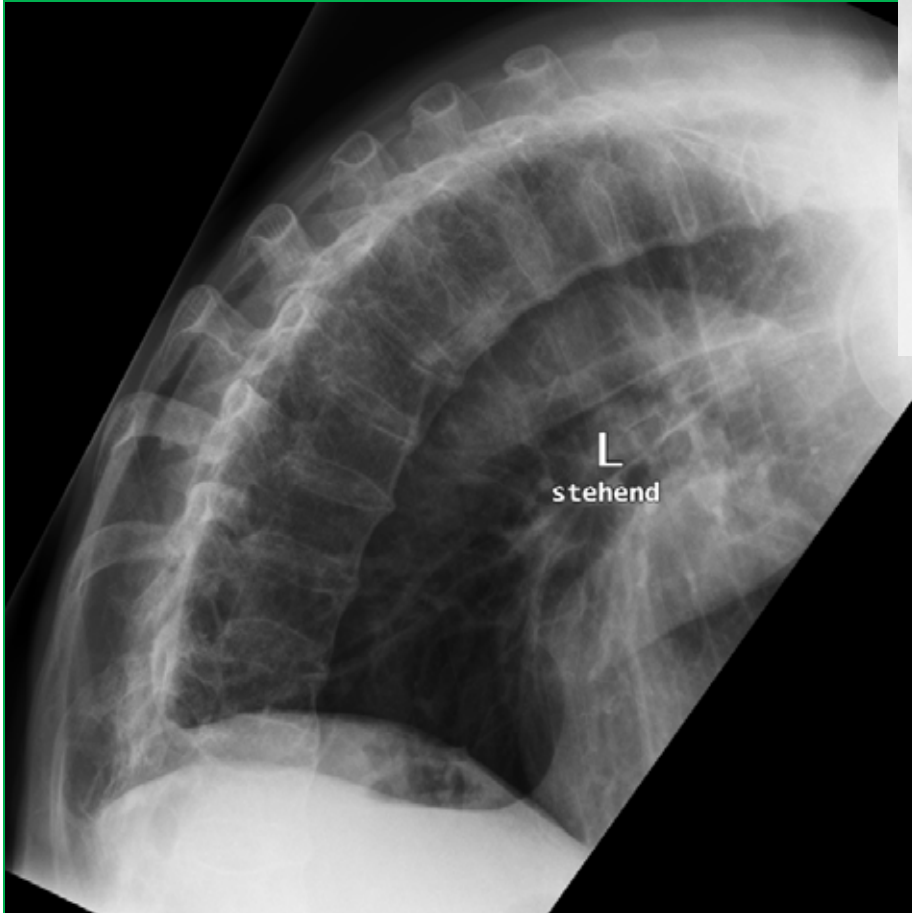


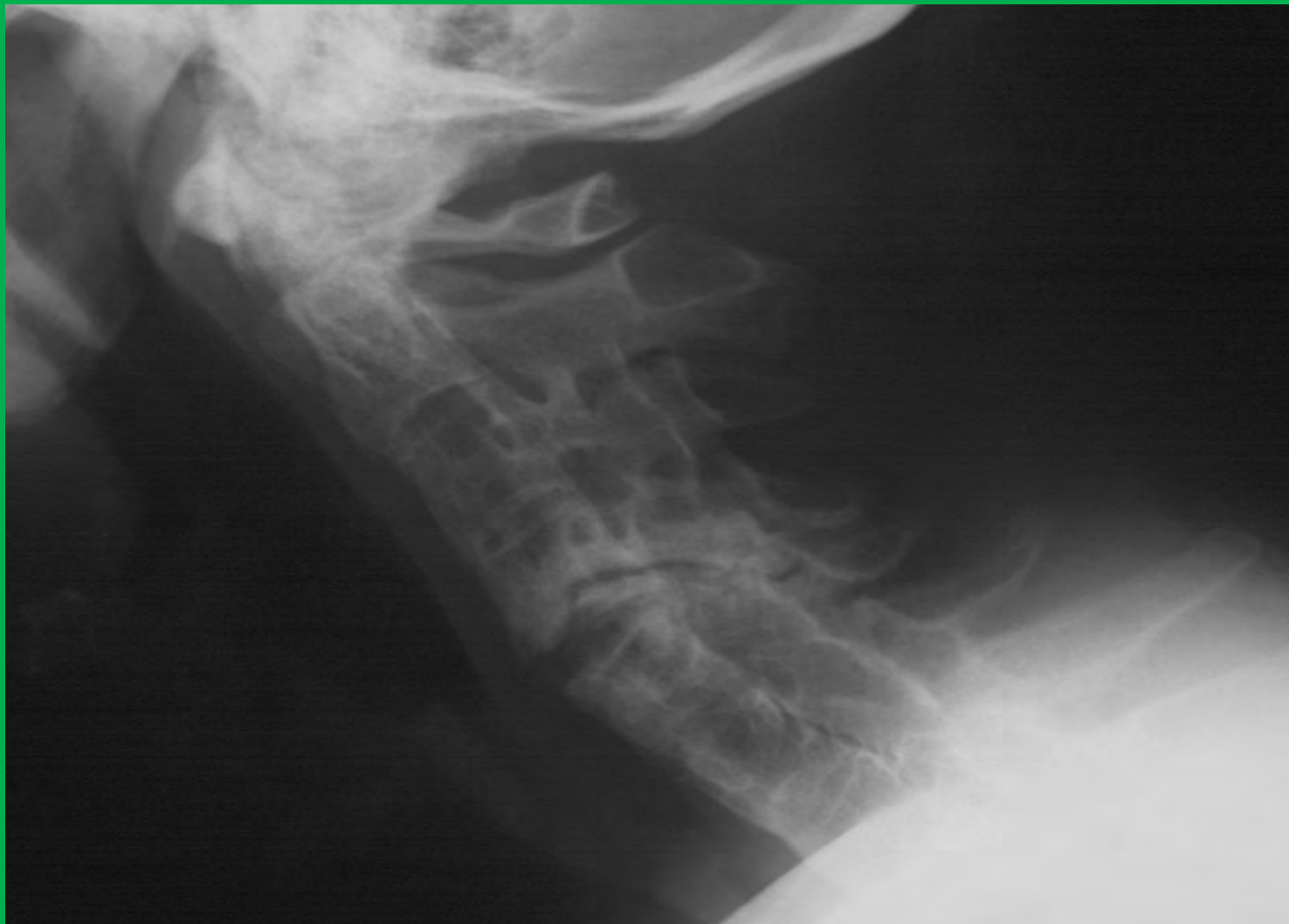Erhaltene Diskusräume

Frakturen:

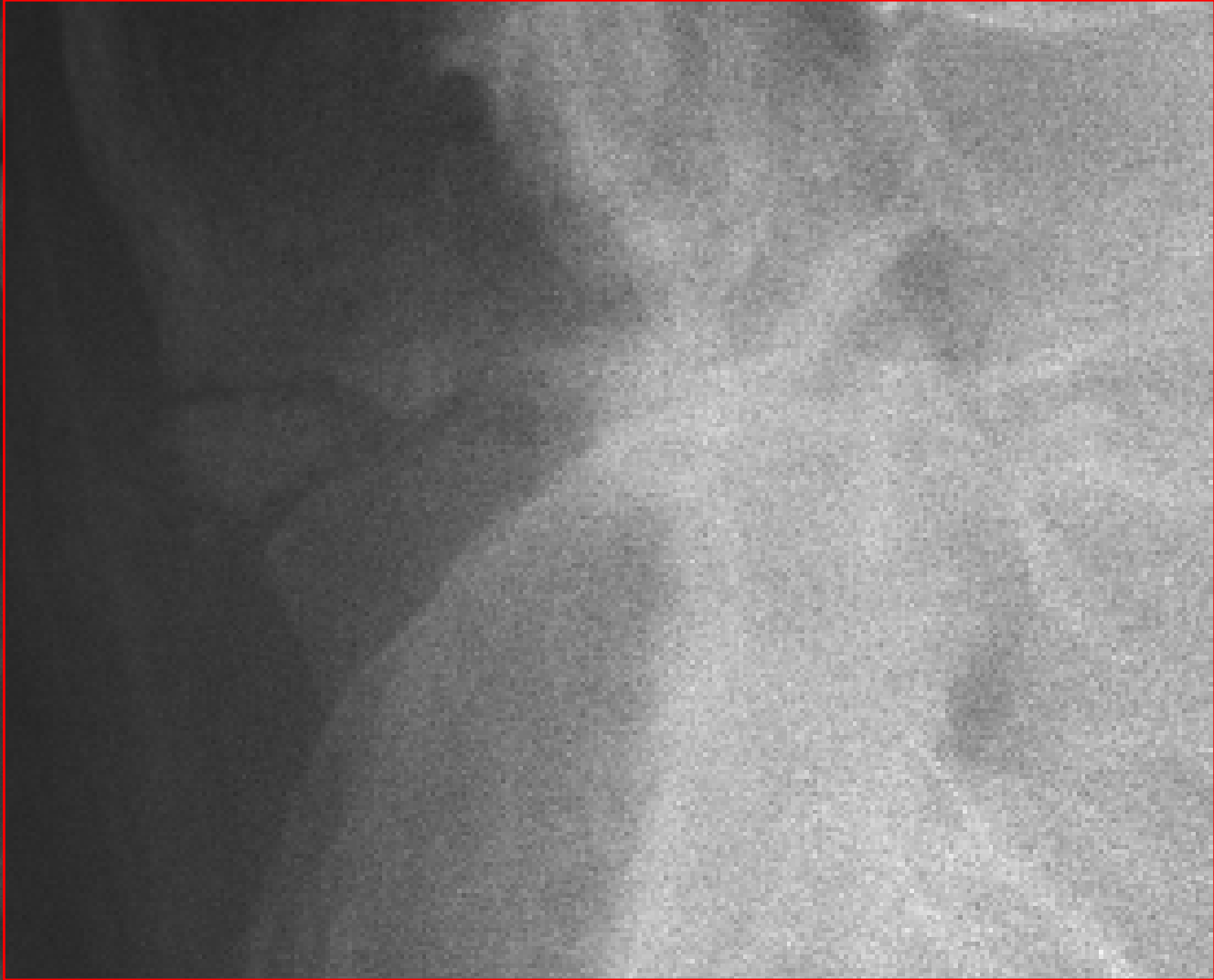
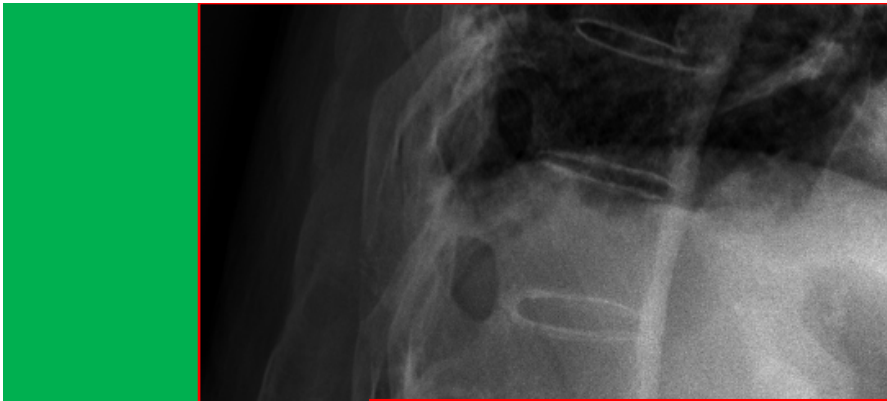
Wirbelkörper (Osteoporose)

Rücken (meistens Höhe Diskus)

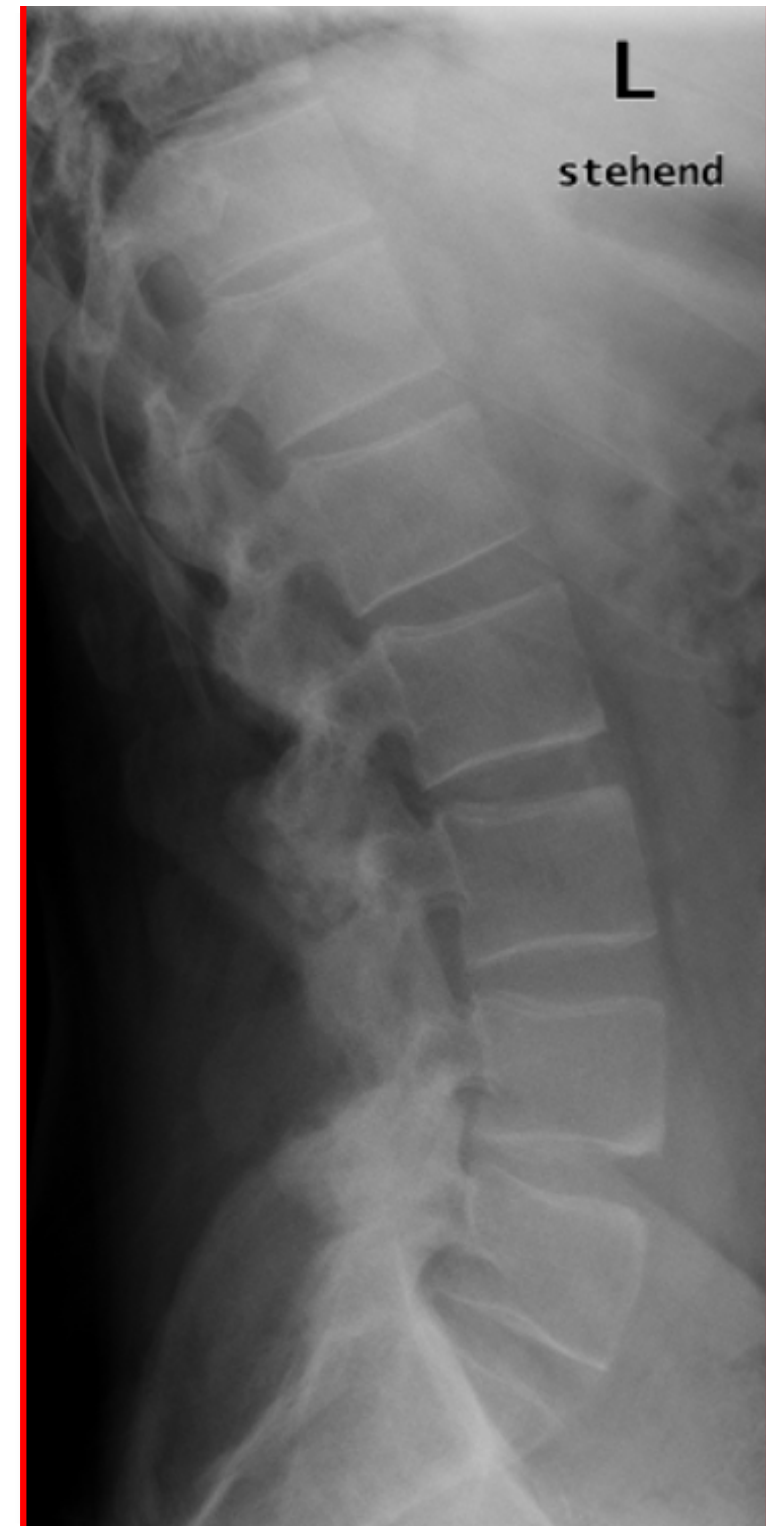



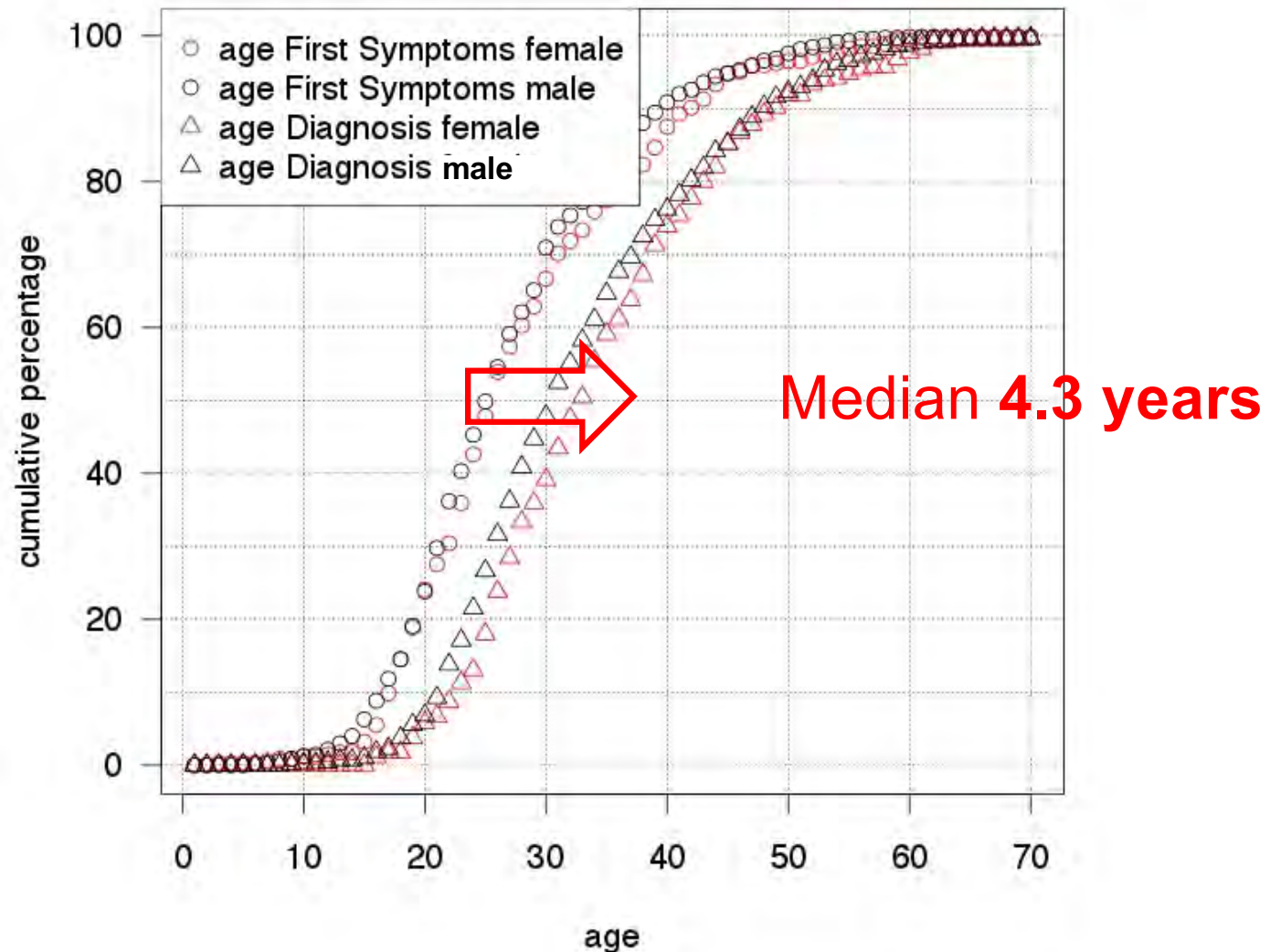
Die Wirbelkörper sind ankylosiert bis auf einen irritierenden, klaffenden Spalt Höhe HWK 4/5. Die Facettengelenke sind ebenfalls fusioniert. Zwischen Atlasbogen und Dens axis sieht man einen Gelenkspalt.




- Diskusräume erhalten
(hilft bei DD Syndesmophyt *versus* Spondylophyt)
- Wirbelkörper:
 - Aufhebung der Konkavität
 - Kastenwirbelbildung
 - Tonnenwirbelbildung
(pathognomonisch)
 - Oft nicht-abgrenzbare Sklerose der Ecken («Shiny Corners»)



Ankylosing Spondylitis: Diagnostic Delay in Switzerland 2011



Early Recognition of Axial Spondyloarthritis for Effective Treatment



- Das Projekt ERASE wurde von einer Expertengruppe* in 2010/2011 entwickelt. Diese Expertengruppe begleitet das Projekt weiterhin.
- Das Projekt ERASE wird von der Schweizerischen Gesellschaft für Rheumatologie unterstützt.

*PD Dr. A. Ciurea (Universitätsspital Zürich), PD Dr. J. Dudler (Hôpital cantonal Fribourg),
Dr. C. Thiel (Rheumatologin, Kloten), Dr. R. Providoli (Internist, Sierre), Prof. P. Villiger (Inselspital Bern)



ERASE Kriterien

Grundversorger

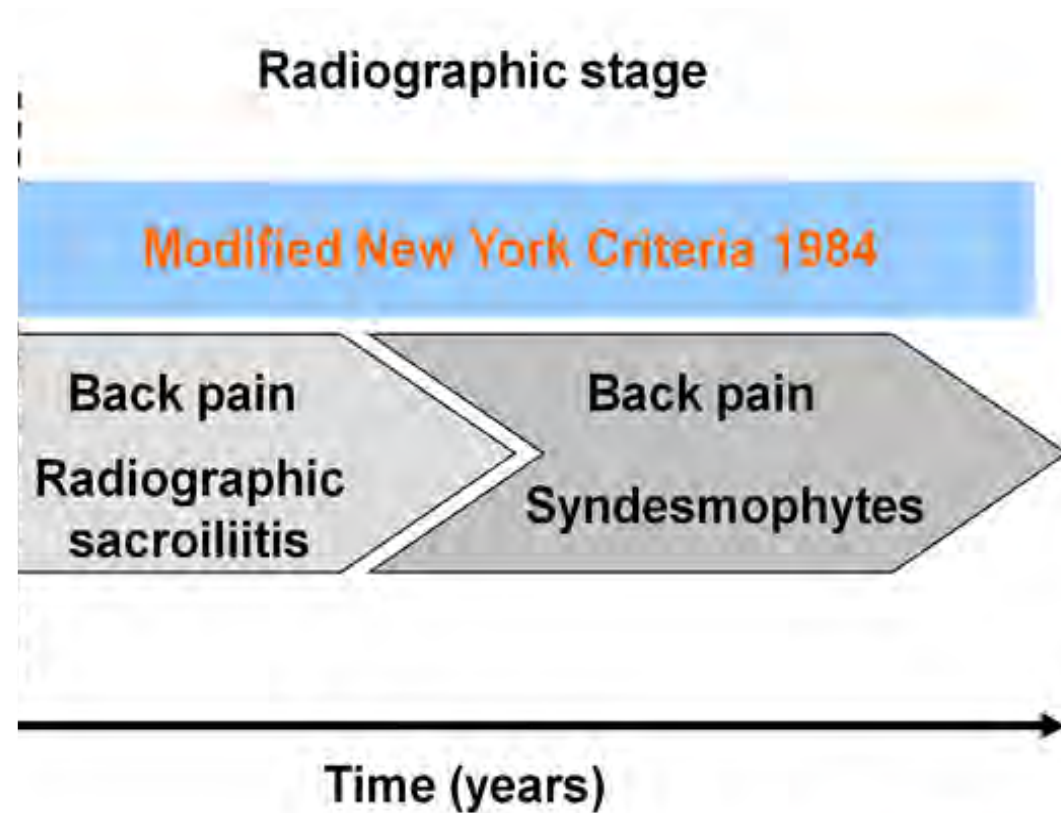
Rheumatologe

Früherkennung von axialer SpA für ein optimales Management

Schweizerische
Gesellschaft für
Rheumatologie

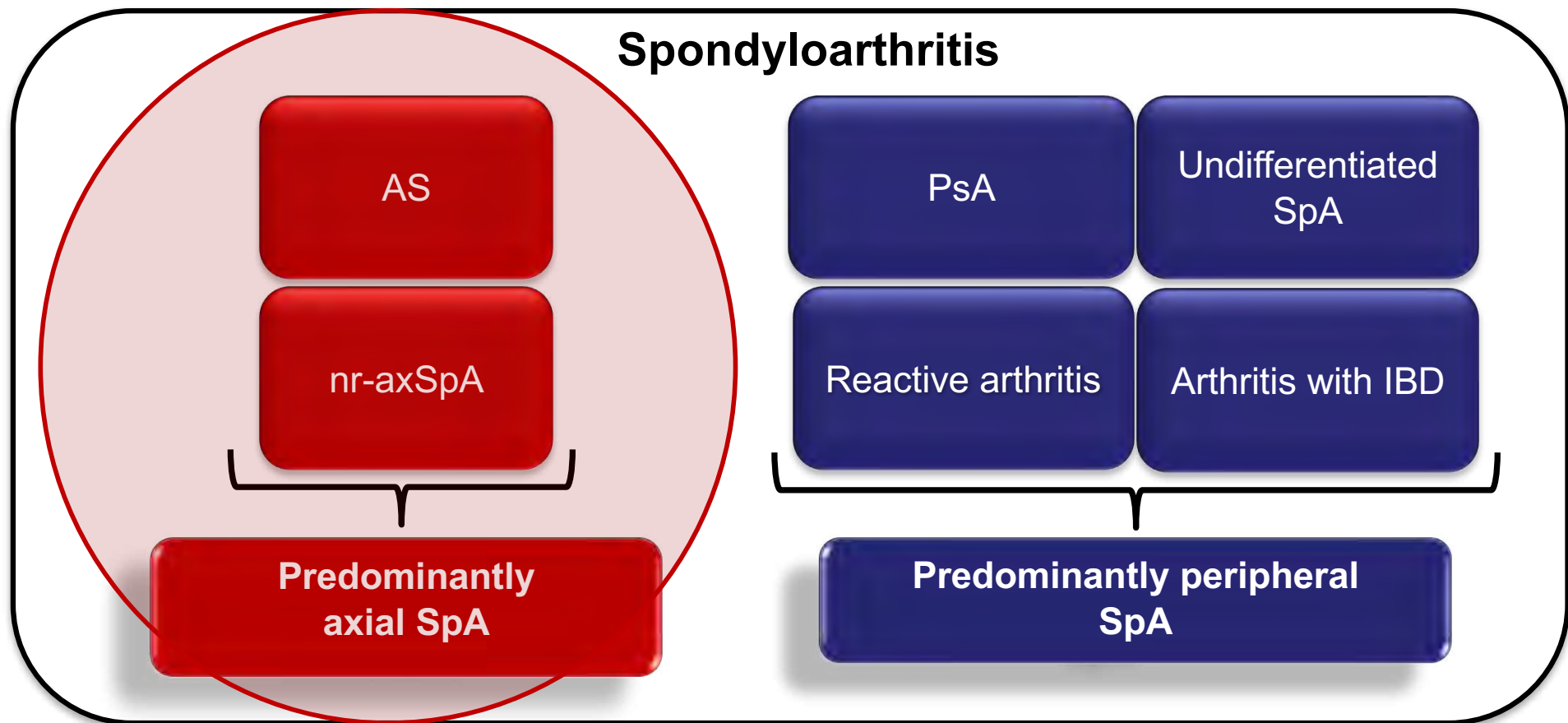
**Chronischer Rückenschmerz > 3 Monate
Erste Symptome vor dem 45. Lebensjahr**

Axial spondyloarthritis (axSpA)





The concept of spondyloarthritis





The ASAS classification criteria for axSpA

- In patients with ≥ 3 months back pain and age at onset < 45 years

Sacroiliitis on imaging*

plus

≥ 1 SpA feature

HLA-B27

plus

≥ 2 other SpA features

SpA features:

- inflammatory back pain
 - arthritis
 - enthesitis (heel)
 - uveitis
 - dactylitis
 - psoriasis
 - Crohn's/colitis
 - good response to NSAIDs
 - family history for SpA
 - HLA-B27
 - elevated CRP
-
- good response to NSAIDs
 - family history for SpA
 - HLA-B27
 - elevated CRP

*Sacroiliitis on imaging

- active (acute) inflammation on MRI highly suggestive of sacroiliitis associated with SpA
- definite radiographic sacroiliitis according to the modified New York criteria

n=649 patients with back pain;

Overall

Sensitivity: 82.9%, Specificity: 84.4%

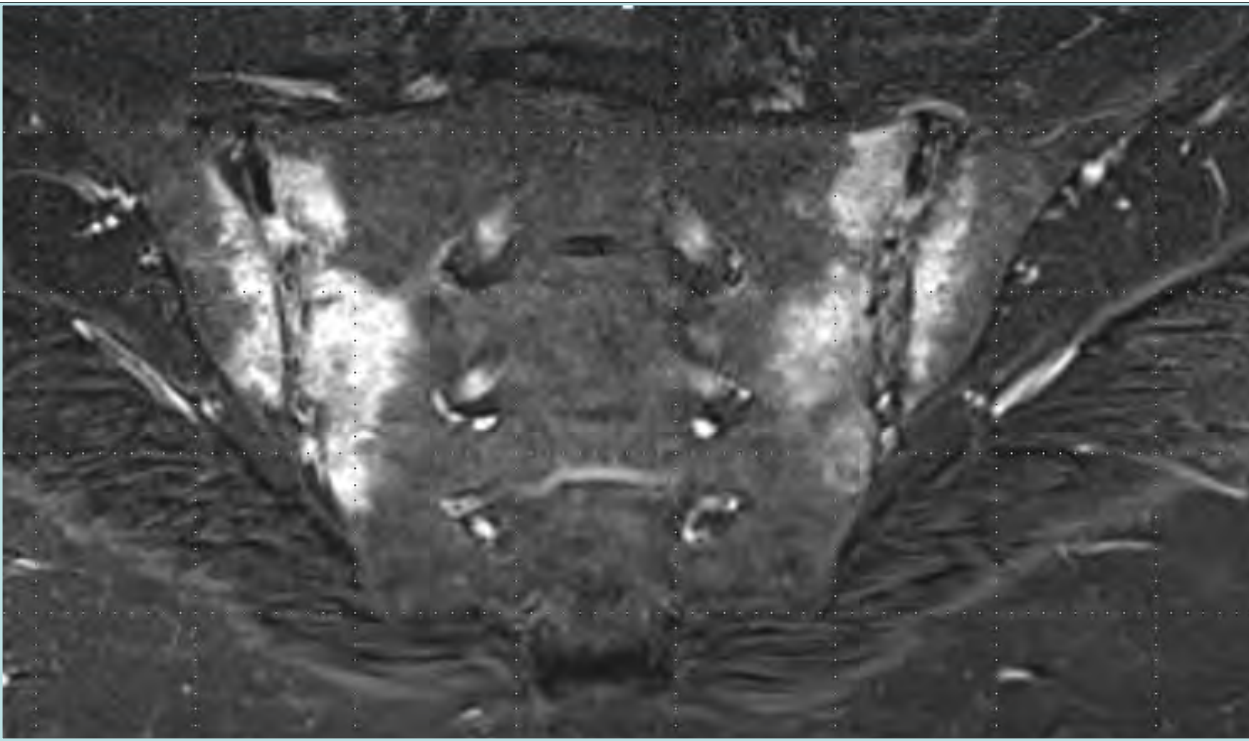
Imaging arm alone

Sensitivity: 66.2%, Specificity: 97.3%

Clinical arm alone

Sensitivity: 56.6%, Specificity: 83.3%

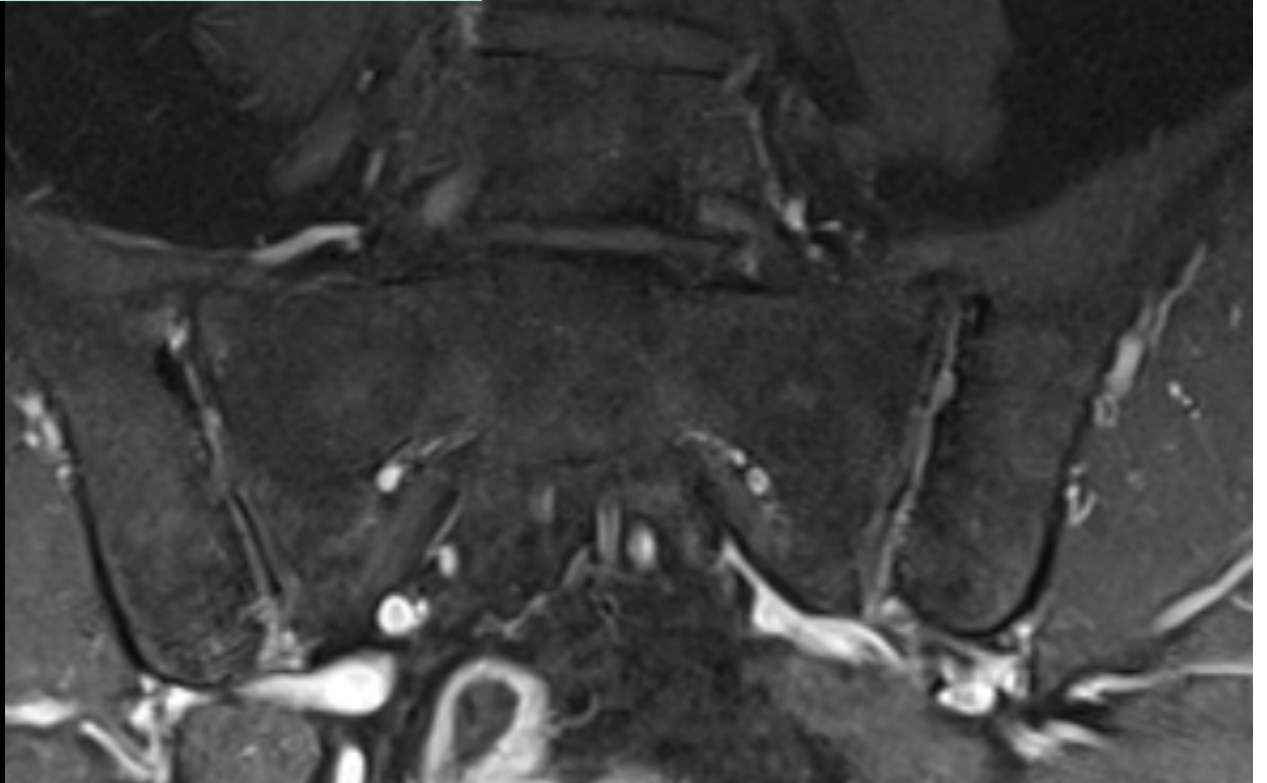





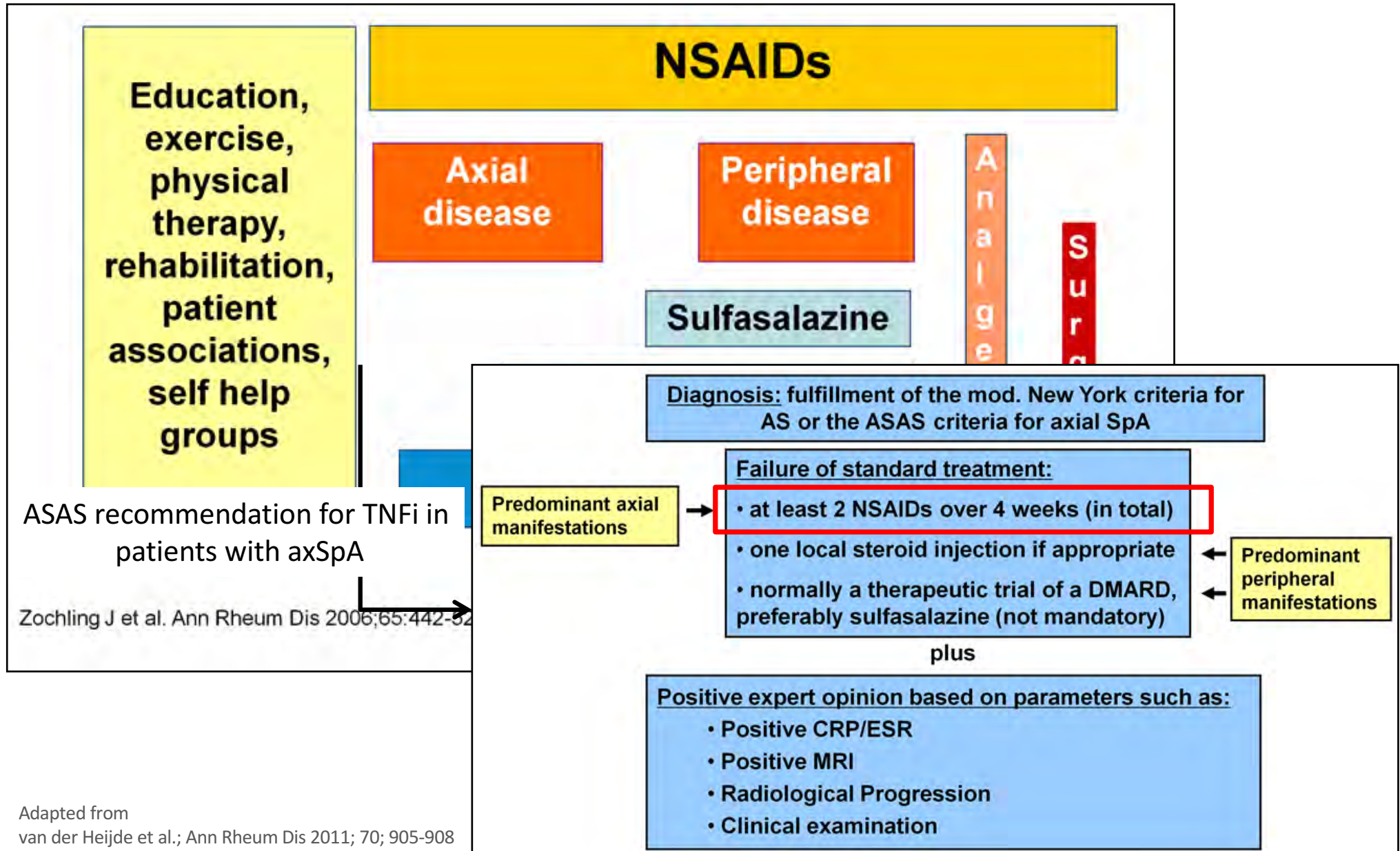
Remicade®



5 Monate

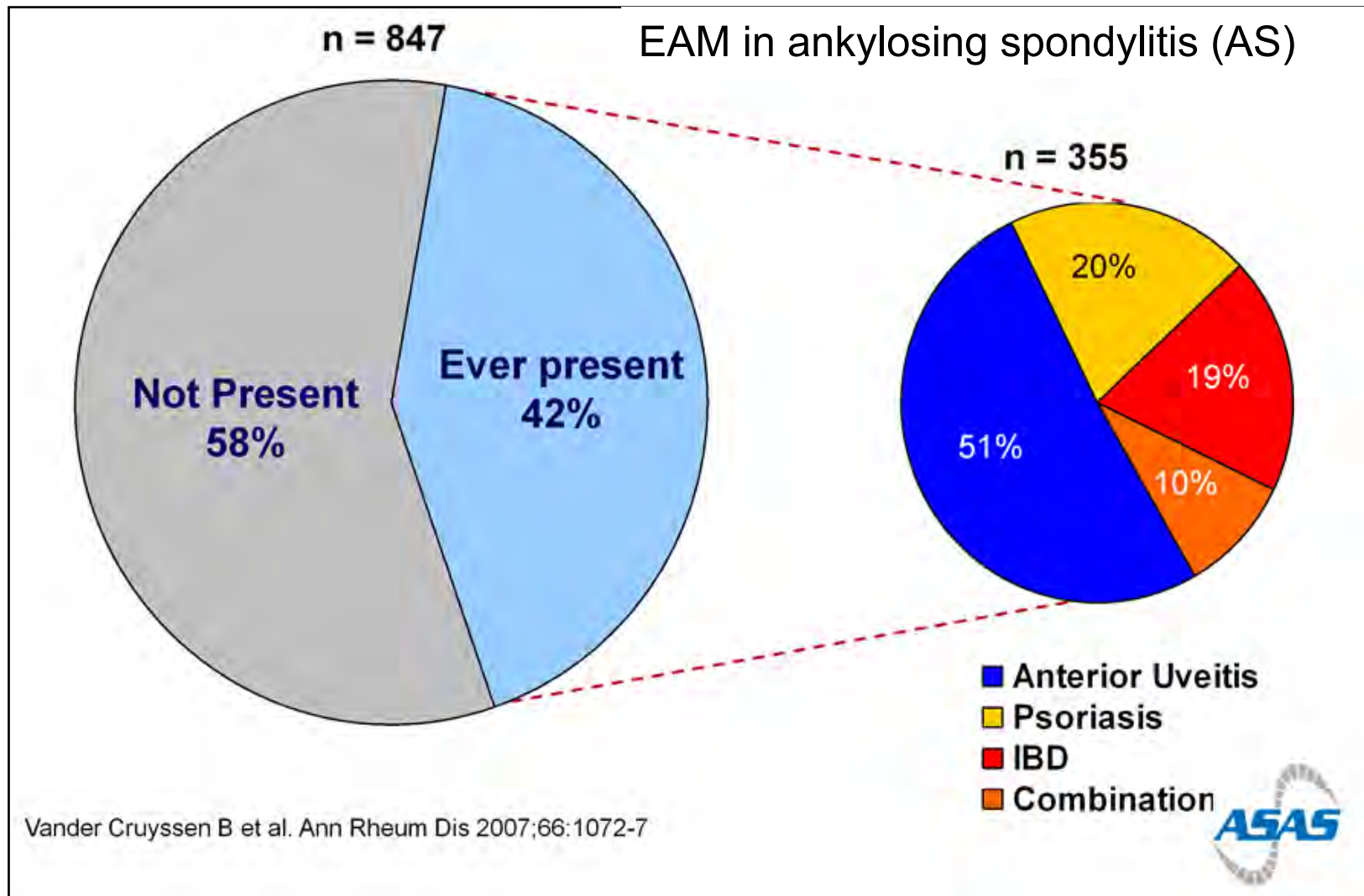


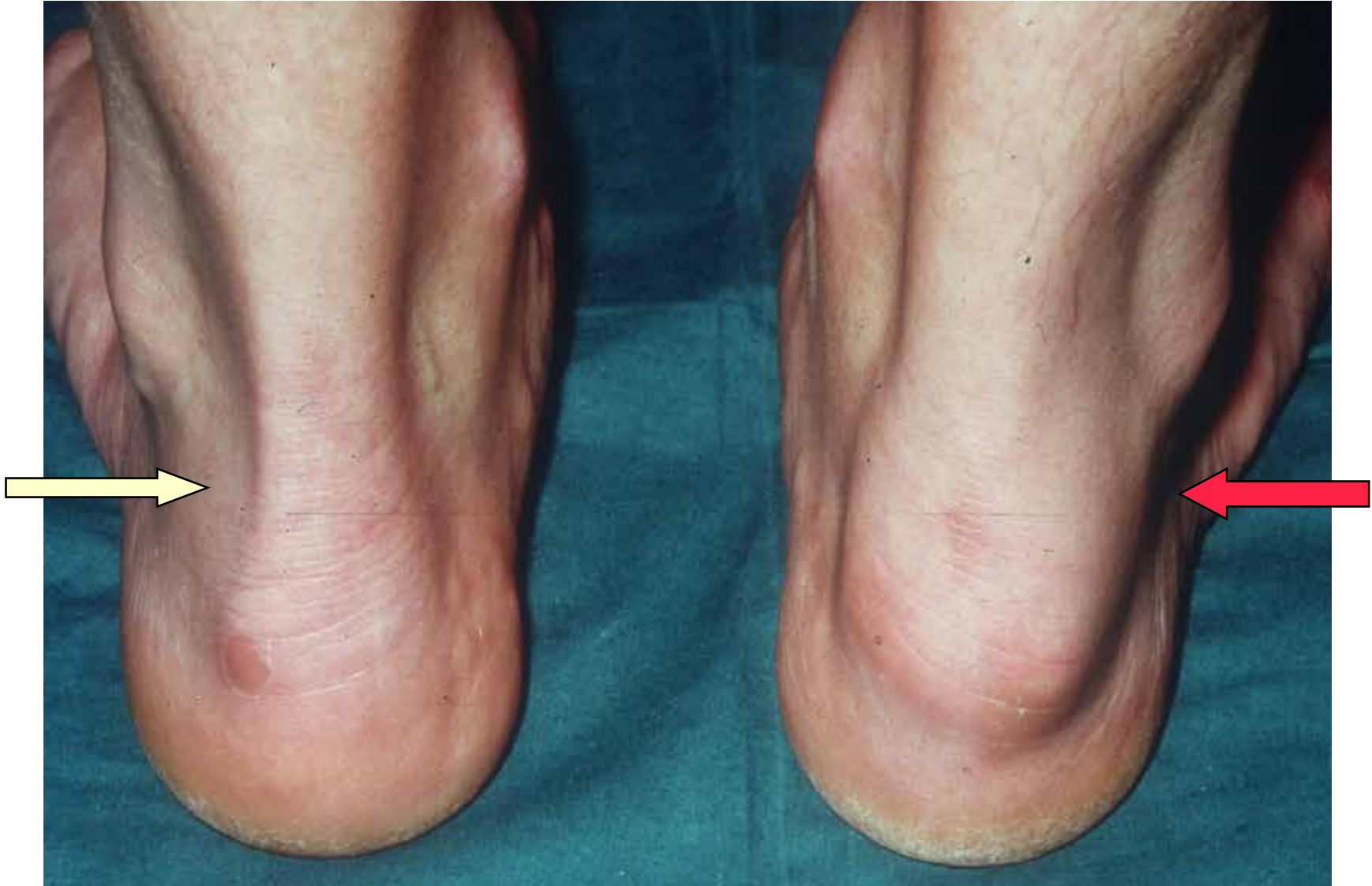ASAS/EULAR recommendations for the management of AS






Extra-articular manifestations (EAM)

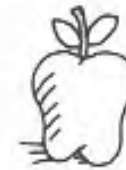



The Far Side[®] February

1307

 Cruel Duke Gessler forces Swiss national hero William Tell to shoot an apple from atop the head of Tell's young son. The reason? William Tell refused to bow to the duke's hat, which was placed on a tall pole in the town's square. (Tell did offer to curtsy, which just made matters worse.)



Tuesday 8



C'mon, Dad!
Shoot the apple!
Shoot the apple!

Unknown to most historians, William Tell had an older and less fortunate son named Warren.